

Guidelines for Autopsy in Custodial Deaths



E-Book Published in 2020

Centre for Enquiry into Health and Allied Themes (CEHAT)

Survey No. 2804 & 2805

Aaram Society Road,

Vakola, Santacruz (E),

Mumbai 400055

Tel.: (91) (22) 26673154, 26673571

Fax: (91) 26673154

Citation: Centre for Enquiry into Health and Allied Themes. (2020). Guidelines for autopsy in custodial deaths. Mumbai, India

ISBN: 978-81-89042-89-9

This publication does not have any copyright. Any part of this publication can be reproduced but not for commercial purposes. All credits need to be acknowledged. If the report is reproduced for any purposes or posted on any website, the publisher should be informed.

Contents

List of Contributors	4
List of External Reviewers	4
List of Abbreviations	5
Introduction	6
Ethical principles in conduct of autopsies	7
Who can carry out the Post Mortem examination	8
Key principles in carrying out an autopsy	10
Video-filming and Photography of a Post Mortem examination	11
The clothed body	12
External examination	12
Current practices in autopsies to rule out SV	14
Internal Examinations	15
Further Testing	17
Concluding the cause of death	19
The autopsy report	19
Autopsy signs for possible torture	19
Audit sheet	23
Annexure 1	24
Annexure 2	29

List of Contributors

1. Aarthi Chandrasekhar
Researcher, CEHAT
2. Anand Grover
Lawyers Collective
3. Baljeet Kaur
Researcher, Quill Foundation
4. Devika Prasad
Commonwealth Human Rights Initiative (CHRI)
5. Dolphy D'Souza
Commonwealth Human Rights Initiative (CHRI)
6. Indrajit Khandekar
Prof. Forensic Medicine MGIMS, Sevagram
7. Jagadeesh N. Reddy
Prof & HOD Forensic Medicine, Bangalore
8. Jayshree Bajoria
Human Rights Watch (HRW)
9. Karunakaran Mathiharan
Prof. Forensic Medicine
10. Kurity Roy
Masum, West Bengal
11. M. Rakesh
Director, Human Rights Law Network (HRLN), Manipur
12. Manisha Tulpule
Advocate
13. Meena Savjani
M.O. Rajawadi Hospital, Mumbai
14. Padma Deosthali
Senior Advisor, CEHAT
15. R. Karunanidhi
Advocate, Peoples Watch Madurai, Tamilnadu
16. Sangeeta Rege
Coordinator, CEHAT
17. Sharib Ali
Program Head, Quill Foundation

List of External Reviewers

1. Anup Surendranath
National Law University Delhi (NLUD)
2. James Lin
International Rehabilitation Council for Torture Victims (IRCT)
3. Mrinal Satish
National Law University Delhi (NLUD)
4. Neetika Vishwanath
National Law University Delhi (NLUD)

List of Abbreviations

BP	Blood Pressure
CrPC	Criminal Procedure Code
CT	Computerised Tomography
DNA	Deoxyribonucleic Acid
ECG	Electrocardiography
FSL	Forensic Science Laboratory
HCP	Healthcare Provider
HIV	Human Immunodeficiency Virus
HBsAg	Hepatitis B surface Antigen
IEA	Indian Evidence Act
IPD	Indoor Patient Department
MoHFW	Ministry of Health and Family Welfare
MLC	Medico Legal Case
MTP	Medical Termination of Pregnancy
OPD	Outpatient Department
PC	Police Constable
PoC	Products of Conception
PEP	Post Exposure Prophylaxis
RMP	Registered Medical Practitioner
STI	Sexually Transmitted Infections
UNCAT	United Nations Convention Against Torture
UPT	Urine Pregnancy Test
VDRL	Venereal Disease Research Laboratory

Introduction

This document has been developed in keeping with international standards set by the Minnesota Protocol on the investigation of potentially unlawful death 2016.¹ The 2013 guidelines for investigating deaths in custody by the International Committee of Red Cross,² and with reference to 2014 guidelines and protocols for medico-legal care for survivors/ victims of sexual violence laid down by the Ministry of Health and Family Welfare, Government of India.³

Autopsies and post-mortem reports, if conducted properly, can be powerful evidence to prove police abuse in custody.⁴ The National Human Rights Commission has, in the past, made efforts to create mechanisms to report custodial deaths. In 1993, the Commission issued a letter to the chief secretaries of all states instructing that all cases of custodial death and rape be reported to it within 24 hours of occurrence, failing which the NHRC would draw an “adverse inference.”⁵ This was followed by another letter in 1995 seeking implementation of the earlier letter and asking the authorities to ensure that all post-mortem examinations of deaths in custody be filmed.⁶ The Commission also wrote to the chief ministers of all states and union territories raising concerns about how post-mortem reports were being documented, inferring that doctors were giving in to pressure from the police and distorting facts.⁷

The Commission recognized the importance of the post-mortem report in determining the cause of death and therefore, issued directions that all records of post-mortem examinations of custodial deaths in jails or police custody be sent to the Commission. Two years later, in 1997, the Commission issued guidelines and a model autopsy form to be followed in all cases of custodial deaths across all states.⁸ More than two decades later, gaps in documentation of autopsies still persist. While the NHRC form makes an effort to create a uniform protocol, the form itself has several gaps. There is also a need for clear guidelines/ instructions to enable doctors to use this uniform protocol.

The review of autopsy reports of young girls and women reveal the forensic biases and stereotypes about rape while carrying out these examinations.⁹ The 2014 guidelines by the Ministry of Health and Family Welfare for medico-legal examination of survivors/ victims of sexual violence need to be followed even in the cases of deaths. These must also include specific instructions on examination of lesbian, gay, bisexual, transgender, queer, and intersex persons.

An analysis of post-mortem reports of custodial deaths show the existing gaps in documentation such as lack of provisional medical opinion or explanation of possible cause of an injury, persistent comments on the status of hymen and vaginal introitus and lack of understanding of limitations of medical evidence.

¹ United Nations Human Rights. (2017). *The Minnesota protocol on the investigation of potentially unlawful death (2016): The revised United Nations manual on the effective prevention and investigation of extra-legal, arbitrary and summary executions*. New York/Geneva: United Nations Human Rights: Office of the High Commissioner. Retrieved from <https://www.ohchr.org/Documents/Publications/MinnesotaProtocol.pdf>

² International Committee of Red Cross. (2013). *Guidelines for investigating deaths in custody*. Geneva: International Committee of Red Cross. Retrieved from <https://www.icrc.org/en/doc/assets/files/publications/icrc-002-4126.pdf>

³ Ministry of Health and Family Welfare. (2014). *Guidelines & protocols: for medico-legal care for survivors/ victims of sexual violence*. New Delhi: Ministry of Health and Family Welfare, Government of India. Retrieved from <https://main.mohfw.gov.in/sites/default/files/953522324.pdf>

⁴ Bajoria, J. (2016, December 19). “Bound by Brotherhood”: India’s failure to end killings in police custody, Human Rights Watch. Retrieved from <https://www.hrw.org/report/2016/12/19/bound-brotherhood/indias-failure-end-killings-police-custody>

⁵ National Human Rights Commission. (1993, December 14). *Letter to all Chief Secretaries on the reporting of custodial deaths within 24 hours*. New Delhi: National Human Rights Commission. Retrieved from http://www.wbja.nic.in/wbja_adm/files/Some%20useful%20National%20Human%20Rights%20Commission%20guidelines.pdf

⁶ National Human Rights Commission. (1995, August 10). *Letter to Chief Ministers of states on the video filming of post-mortem examinations in cases of custodial deaths*. New Delhi: National Human Rights Commission. Retrieved from http://www.wbja.nic.in/wbja_adm/files/Some%20useful%20National%20Human%20Rights%20Commission%20guidelines.pdf

⁷ National Human Rights Commission. (1997). *Guidelines on custodial deaths/ rapes*. New Delhi: National Human Rights Commission. Retrieved from <https://nhrc.nic.in/sites/default/files/sec-1.pdf>

⁸ National Human Rights Commission. (1997, March 27). *Letter to chief ministers/ administrators of all states/ union territories with a request to adopt the model autopsy form and the additional procedure for inquest*. New Delhi: National Human Rights Commission. Retrieved from http://www.wbja.nic.in/wbja_adm/files/Some%20useful%20National%20Human%20Rights%20Commission%20guidelines.pdf

⁹ Human Rights Watch & Centre for Enquiry into Health and Allied Themes (2018, October 26-27). *Medico-legal guidelines for custodial torture and autopsies in custodial death cases*. PowerPoint presented at Conference on Strengthening legal protection against torture in India, New Delhi: Commonwealth Human Rights Initiative.

Definition of Custodial Death

The Minnesota Protocol defines custodial death as death that has occurred in custody, where the state is involved, where the person was in the custody of the State or where the State may have failed to meet the obligation to protect life,¹⁰

State agents include the police, military, or paramilitary personnel/ or groups, prison authorities or those acting under the direction of the State.

India's Domestic and International Legal Obligations

In the absence of a domestic law, courts have used international conventions and norms to rule on fundamental rights of persons.¹¹

Article 21 of the Indian Constitution states that "No person shall be deprived of his life or personal liberty except according to a procedure established by law." Custodial deaths are therefore, in conflict of the right to life and a failure of the state to protect the life of the person. The Supreme Court of India, in *D.K. Basu v. West Bengal* interpreted article 21 to include "within itself a guarantee against torture and assault by the States or its functionaries."¹² Article 3 of the Universal Declaration of Human Rights also recognizes the right to life, liberty and security of the person.¹³

Article 6 of the International Covenant on Civil and Political Rights, to which India is a party, recognises the right to life of every human being. Article 7 specifies that no one shall be subjected to torture or to cruel, inhuman or degrading treatment or punishment.

The state is accountable when it fails to protect, preserve or respect the right to life and must investigate such unlawful deaths. Healthcare providers form part of the investigation procedure owing to their role in thorough documentation of the autopsy in custodial deaths.

Ethical Principles in Conduct of Autopsies

Healthcare professionals (HCP) must adhere to highest standards of ethics in carrying out their role.

- Healthcare providers are bound by the Hippocratic oath of 'do no harm', irrespective of the background of the victim. This is also aligned with the principle of non-maleficence.
- The HCP must ensure fairness in his/ her practice applying the principle of justice.
- HCPs must treat the family of the victim with dignity.
- HCPs must handle the body of the deceased with dignity.

Failure to document torture and existing findings implies complicity in crime, albeit in an indirect manner and amounts to breach of medical ethics by the doctor. Doctors must exercise objectivity, irrespective of whom they are employed by –health or home department or private body.

Duties and Obligations of Doctors¹⁴ To ensure establishing identity of the deceased

- To reveal cause and circumstances of the death
- To exercise care and skill in this work

Aims of autopsy:

¹⁰ *The Minnesota protocol on the investigation of potentially unlawful death (2016)*, Page 1

¹¹ Supreme Court of India (1997, August 13). *Vishaka v. State of Rajasthan*. New Delhi: Supreme Court of India. Retrieved from <https://indiankanoon.org/doc/1031794/>

¹² Supreme Court of India (1996, December 18). *D.K. Basu, Ashok K. Johari v. State of West Bengal, State of U.P.* New Delhi: Supreme Court of India. Retrieved from <https://indiankanoon.org/doc/501198/>

¹³ United Nations. (2015). *Universal declaration of Human Rights*. New York: United Nations. Retrieved from https://www.un.org/en/udhrbook/pdf/udhr_booklet_en_web.pdf

¹⁴ *The Minnesota protocol on the investigation of potentially unlawful death (2016)*, Page 27

- Record identifying characteristics of the deceased
- Record injuries and other findings including lesions, infections, bleeding
- Draw conclusions about the identity of the deceased
- Draw conclusions about the cause of death and factors contributing to death

The autopsy report, therefore, is an essential document in understanding the circumstances that may have led to the death of the victim and in documenting possibility of torture and ill-treatment.

Who Can Carry out the Post-Mortem Examination

- Trained medical experts can conduct the autopsy, preferably a team of two or more medical experts of whom at least one is a forensic medicine expert.¹⁵
- Examination should be done by forensic experts. Where forensic experts are not available at the time of autopsy, the report and relevant samples must be sent to a forensic expert for their opinion/validation.
- Where necessary, forensic experts from nearby hospitals may be called upon and included in the team of medical experts carrying out the autopsy.
- Both private and public institutions can carry out the autopsy so as to ensure independent investigations.
- It is common practice for the post-mortem to be conducted by attendants or mortuary cleaners who are not medical professionals. These attendants, often belonging to Dalit community, “formerly untouchables” are made to carry out the procedure due to notions of purity and pollution.¹⁶ This practice is illegal must stop.
- No police personnel should be present at the time of conduct of the autopsy to ensure that their influence on the examination/ investigation is avoided.

Information to Next of Kin about Autopsy Procedures

- Intimation to the next of kin is the responsibility of the police; the medical examiner must treat the next of kin of the victim with dignity.
- Where possible, the next of kin must be informed of the time of autopsy and be allowed representation through a family doctor or lawyer.
- While consent of the next of kin is not a pre-requisite for carrying out autopsy in custodial death, the doctor must inform the next of kin about the process.
- Where the organs of the victim must be retained for further forensic examination, it would be good practice to inform the next of kin of the same. The doctor must also explain the procedure for returning the organs after conclusion of forensic examinations.
- The body of the victim must be handed over to the next of kin in a dignified manner that will allow them to perform customary funeral rites at the earliest.
- The doctor must also provide a ‘cause of death’ certificate if it has not been done already.
- The practice of police certifying death or cause of death is unscientific, erroneous and could lead to bias. Such a certificate must only be issued by the doctor.
- Any personal belongings of the victim must also be handed over to Investigating Officer as soon as possible after completing necessary documentation.
- The doctor must offer first line psychological support to the next of kin and make counselling services available where possible; nurses may also be involved in conveying the progress and results as well as first line psychological support.
- The doctor must be sensitive and unbiased in communicating the findings of the autopsy to the next of kin of the victim.
- Copy of the post-mortem report and videography must be given to the next of kin free of cost as soon as it is available. The doctor must ensure safety and privacy while handing over the document.

¹⁵ Mathiharan, K. (2005). Origin and development of forensic medicine in India. *The American Journal of Forensic Medicine and Pathology*, 26(3), 254-260.

¹⁶ Sengupta, R. (2018, September 7). The autopsy report. *Livemint*. Retrieved from <https://www.livemint.com/Politics/Lofa7q6gweBypR05loERrO/The-autopsy-report.html>

- Teaching hospitals that want to use the autopsy to train students must seek permission of the board and also convey the same to the next of kin or put a visible sign that explains that this is for the purpose of medical education process.
- Doctor must record means of identification – by one next of kin in the presence of the police officer with signature on the original post-mortem report before commencing autopsy.
- The autopsy must be carried out within 24 hours of death of the person in accordance to section 176 of the Criminal Procedure Code.* Where the time period exceeds 24 hours since death, the doctor must document exact time of autopsy with reasons for delay if any and also time since death.

A critical review of autopsy guidelines has highlighted that there are different directives for different states, including for who can conduct an autopsy and when it can be conducted. There are different guidelines, proforma and rules for autopsy work all over India. This leads to a confusing and compromising situation as far as medico-legal autopsies are concerned.¹⁷

Equipment required for the purpose of carrying out a post-mortem examination¹⁸:

- Scalpels of different sizes
- Organ knives of 6" and 10" blade
- Cartilage knives of 5¼" and 4" blade
- Brain knife 10" blade
- Resection knife
- Cotlin
- Bistoury – probe pointed
- Scissors – blunt and sharp – 8", 6" and 11" for bowel
- Fine point Mayo scissors 5¼" also dissecting scissors – 5"
- Bone cutters – 10" straight and angled
- Rib shears 9½"
- Dissecting forceps of different sizes, Spencer-Wells forceps
- Barnard's saws 9" and 11" and an electric autopsy saw with accessories
- Lands hinged coronet
- Set of half curved and double curved post-mortem needles and twines
- Probe with eye
- Chisels straight and spine with locating point
- Gouge ¾" blade
- Hammer with wrench end
- Box wood mallet with metal bands
- A metal or plastic measuring tape
- Measuring and graduated glass containers
- China plates
- Basins to contain water
- A pair of thick post-mortem or surgical gloves
- Sponges
- Balance for weighing organs
- Wide mouthed, glass bottles (with glass stoppers) of about one litre capacity to contain portions of viscera and vials for collecting blood samples for grouping/ alcohol concentration
- A few glass slides, bowls, trays and test tubes
- A hand lens, particularly useful for distinguishing apparently incised wounds from lacerated

* According to CrPC section 176, where a person dies in custody, "the Judicial Magistrate or the Metropolitan Magistrate or Executive Magistrate or police officer holding an inquiry or investigation, as the case may be, under sub-section 1A (where any person dies or disappears) shall, within twenty four hours of the death of a person, forward the body with a view to its being examined to the nearest Civil Surgeon or other qualified medical person appointed in this behalf by the State Government, unless it is not possible to do so for reasons to be recorded in writing."

¹⁷ Sirohiwal, B., Sharma, L. & Paliwal, P. K. (2013). Critics and sceptics of medico-legal autopsy guidelines in Indian context. *Journal of Indian Academy of Forensic Medicine*, 35(4), 373-377.

¹⁸ Kannan, K. (2016). *A textbook of medical jurisprudence and toxicology* (25th ed.). Haryana: LexisNexis Butterworths.

wounds on the scalp and over hard bones

- Aprons
- Adhesive tape
- Facilities for X-rays and photography

Chemicals

- Preservatives – common salt, rectified spirit
- Fixative – Formalin 10 percent
- Glycerine – for preserving brain in suspected rabies case
- Liquid paraffin – for topping blood sample in death due to suffocation from inhalation of irrespirable gases
- Miscellaneous – post-mortem forms or labels, envelopes, antiseptic soap or solution, disinfectants, sealing wax, colour corrected shadow-less lamp

Key Principles in Carrying out an Autopsy

- Date, start and finishing times and the place of the autopsy should be recorded.
- The name(s) of the forensic pathologist prosecutor(s)/ doctors, the participating assistant(s) and all other persons present during the autopsy should be recorded, including the medical and/ or scientific degrees and professional, or administrative affiliations(s) of each. Each person's role in the autopsy should be indicated. If there are multiple doctors, one should be designated as the principal doctor with authority to direct the performance of the autopsy.
- Adequate photographs are crucial for thorough documentation of autopsy findings and for enabling them to be independently reviewed.
- Photographs should be taken using a high-quality camera/ lens. If high-quality equipment is not available, then other equipment, such as mobile phones, may be acceptable, bearing in mind that it is important for the photographs to be of sufficient quality to enable the autopsy findings to be independently reviewed. Each photograph should contain a ruled reference scale and an identifying case name or number. A description of the camera and the lighting system should be included in the autopsy report. If more than one camera is used, the identifying information should be recorded for each. Photographs should also include information indicating which camera took each picture, if more than one camera is used. The identity of the person taking the photographs should be recorded.
- Serial photographs reflecting the course of the external examination should be included. Photograph the body prior to and following undressing, washing, shaving or hair cutting.
- Close-up photographs should be supplemented with distant and/ or medium-range photographs to permit the orientation and identification of the close-up photographs.
- Photographs should be comprehensive and must confirm the presence and details of all demonstrable signs of injury or disease commented upon in the autopsy report. Photographs of injuries should include a scale with the autopsy number.
- After the body has been washed or cleaned, identifying facial features should be portrayed with photographs of a full-frontal aspect of the face and right and left profiles of the face.
- Videography of the entire autopsy procedure should be done as mandated by NHRC. Videography of autopsy procedure is compulsory in all autopsies of custodial deaths as per National Human Rights Commission. Videography should be carried out by a professional videographer having knowledge both in technical aspects of videography and autopsy.
- If it is available, then CT scanning of the whole body enclosed in the body bag should be undertaken. (If this is done, further consideration of the need for plain X-ray films or radiographs will still be needed). In the likely event that CT (cross-sectional) imaging is not available, the body should be radiographed with plain X-rays or radiographs before it is removed from its packaging. X-rays or radiographs should be repeated both before and after undressing the body. Fluoroscopy (looking for foreign bodies such as projectiles) may also be performed. The following X-rays or radiographs may also be required:
 - Dental X-rays or radiographs may be necessary for identification purposes.

- Any skeletal system injury should be documented by X-ray or radiographs. Skeletal X-rays or radiographs may also record anatomic defects or surgical procedures. Check especially for fractures of the fingers, toes and other bones in the hands and feet.
- X-rays or radiographs should be taken in gunshot cases to aid in locating the projectile(s). Any projectile or major projectile fragment seen on an X-ray or radiographs must be recovered, photographed, recorded as an exhibit and secured.
- Other radio opaque objects (such as knife fragments) should also be documented with X-rays or radiographs, removed, photographed, recorded as exhibits, and secured. If necessary, for the purposes of identification, metallic prostheses must be removed and examined, and any identifying features recorded, photographed and secured. Any pacemakers must be removed, especially if cremation is to take place, as they will explode in a fire. Skeletal X-rays or radiographs can assist in determining the age and developmental status of children and young adults.
- In case of alleged firearm-related deaths, the dead body should be subjected to radiological examination (X-rays/ CT Scan) prior to autopsy.
- Details of the medical history of the victim from their kin as well as details recorded by the prison doctor for the period during which the victim had been incarcerated. In cases where it is found that the death was caused due to an aggravation of the ongoing illness, the doctor(s) could notify the Magistrate, who could direct that the family and prison doctor be produced and relevant information be collected from them.

Video-Filming and Photography of a Post-Mortem Examination

At the time of filming a post-mortem examination, the voice of the doctor conducting it should be recorded. The doctor should narrate his prima-facie observations while conducting the examination.

A total of 20-25 coloured photographs covering the whole body should be taken. Some photographs of the body should be taken without removing the clothes. The photographs should include the following:

- Profile photo-face (front, right lateral and left lateral views), back of head
- Front of body (up to torso-chest and abdomen) – and back
- Upper extremity - front and back Lower extremity – front and back
- Focusing on each injury/ lesion-zoomed in after properly numbering the injuries[†]
- Internal examination findings (2 photos of soles and palms each, after making incision to show absence/ evidence of any old/ deep seated injury).
- Photographs should be taken after incorporating post-mortem number, date of examination and a scale for dimensions in the frame of photographs itself.
- While taking photographs, the camera should be held at right - angle to the object being photographed.
- Video-filming and photography of the post-mortem examination should be done by a person trained in forensic photography and videography. A good quality digital camera with 10X optical zoom and minimum 10 megapixels should be used.

Guidelines for video-filming and photography of post-mortem examination in case of death in police action¹⁹

In case of deaths in police action, while conducting post-mortem examination of the deceased, photographs of the deceased should be taken and the post-mortem examination of the deceased should

[†] For firearm injuries, measure the distance from heel as well as midline must be in respect of each injury to help in reconstruction of events.

¹⁹ National Human Rights Commission. (n.d.). *Guidelines for video-filming and photography of post-mortem examination in case of death in police action*. Retrieved from http://nhrc.nic.in/sites/default/files/Guidelines_for_video_photography_of_PME_death_in_police_action.pdf

be video filmed. The video film and photographs should be sent to the National Human Rights Commission.

The aim of video-filming and photography of post-mortem examination should be to:

- Record the detailed findings of the post-mortem examination, especially pertaining to marks of injury and violence which may suggest custodial torture.
- Supplement the findings of post-mortem examination (recorded in the post-mortem report) by video graphic evidence so as to rule out any undue influence or suppression of material information.
- Facilitate an independent review of the post-mortem examination report at a later stage if required.

The following precautions should be taken before conducting a post-mortem examination:

- Both hands of the deceased need to be wrapped in white paper bags before transportation. Afterwards, the dead body should be covered in special body bags having zip pouches for proper transportation.
- Clothing on the body of the deceased should not be removed by the police or any other person. It should be collected, examined as well as preserved and sealed by the doctor conducting the autopsy, and should be sent for further examination at the concerned forensic science laboratory.
- A detailed note regarding examination of the clothing should be incorporated in the post-mortem examination report by the doctor conducting the autopsy.

The Clothed Body

- Before clothing is removed, the clothed body should be photographed.
- If it has not already been done, and is indicated by the circumstances, the hands should now be swabbed for firearm discharge residues. If not done at the scene, the clothed body should be carefully inspected for any traces that might constitute evidence. If any traces are found, they should be described, retrieved, recorded as exhibits and secured.
- The clothing should be carefully removed (preferably without damage) over a clean sheet or body pouch. The clothing and any jewellery should all be individually examined, described, recorded, labelled, photographed and secured.

External Examination

The external examination, focusing on a search for external evidence of injury, is in most cases a critical part of the autopsy.

- All of the body area must be photographed.
- The body must be examined and the deceased's apparent age, height, weight, sex, head-hair style and length, nutritional status, muscular development, and color of skin, eyes and hair (head, facial and body) must be examined and recorded.
- In babies, the head circumference, crown-rump length, mid-arm circumference and crown-heel length should also be measured.
- The degree, location and fixation of rigor and livor mortis should be recorded.
- Body warmth or coolness and state of preservation should be noted as should any decomposition changes, such as skin slippage. The general condition of the body should be evaluated and note taken of adipocere formation, maggots, eggs, pupae, or anything else that suggests the time or place of death.
- With all injuries, their location (related to static anatomic landmarks), size, shape, surrounds, pattern, contents, colour, course, direction and depth must be recorded. Injuries resulting from therapeutic measures should be distinguished wherever possible from those unrelated to medical treatment.
- In the description of firearm wounds, note the presence or absence of marginal abrasions, lacerations or defects in the margins of the wound, foreign contents within the wound, singeing or grease marking the margins of the wound, and soot and/ or gunpowder stippling or tattooing around the wound. If firearm discharge residue is present, this should be photographed and

preserved for analysis. It should be determined whether the bullet wound is an entry or exit wound. If an entry wound is present and no exit wound is seen, the projectile must be found and secured or accounted for. Gunshot injuries must be distinguished as close range or long range. Range of firing may be determined on the basis of residue on the clothes and wound characteristics as described above. The detailed wound characteristics in case of firearm wounds have been explained in forensic textbooks.

- All injuries should be photographed, and labelled with the autopsy identification number on a scale that is oriented parallel or perpendicular to the injury. Shave hair where necessary to clarify an injury and take photographs with a photographic scale both before and after shaving. Save all hair removed from the site of the injury. Take photographs before and after washing the site of any injury. Wash the body only after any blood or material that may have come from.
- Examine the skin. Note and photograph with a photographic scale any scars, areas of keloid formation, tattoos, prominent moles, areas of increased or decreased pigmentation, and anything distinctive or identifying, such as birthmarks. Note any bruises and incise them for delineation of their extent. Some, if not all of them, should be excised for microscopic examination as this may be useful for assessing the time between injury and death.
- The head and genital area should be checked with special care. Note any injection sites or puncture wounds.
- Note any bite marks; these should be photographed to record the dental pattern, swabbed for saliva testing (before the body is washed), and excised for microscopic examination. The evaluation of bite marks is highly contentious and they should also be evaluated by a forensic dentist with training and experience in such evaluation, if possible. The use of such expertise should always be explored wherever the doctor conducting autopsy is inexperienced in documenting and analysing bite mark evidence.
- Note any burn marks and assess the possible cause (e.g. burning rubber, a cigarette, electricity, a blowtorch, acid, hot oil) by sampling for histology and other analysis if possible. Note any gunpowder residue on the hands. Document this photographically and save it for analysis. Excise any suspicious areas for microscopic examination, as it may be possible in some circumstances to distinguish between burns caused by electricity and those caused by heat or cold.
- Identify and label any foreign object that is recovered, including its relationship to specific injuries. Foreign objects should be placed in a container that should be processed/ analysed in accordance with established procedures to maintain the chain of custody. Do not scratch the sides or tip of any projectiles. Photograph each projectile and large projectile fragment with an identifying label, and secure them individually in a sealed, padded and labelled container in order to maintain the chain of custody.
- Examine the head and external scalp, bearing in mind that injuries may be hidden by the hair. Shave hair where necessary. Check for fleas and lice, as these may indicate unsanitary conditions prior to death. Note any alopecia, as this may be caused by malnutrition, heavy metals (e.g. thallium), drugs, or traction. Pull – do not cut – 20 representative head hairs and save them, as hair may be useful for detecting some drugs and poisons. (It may also be of value in stable isotope analysis).
- Examine the teeth and note their condition on the dental charts. This should be performed by a forensic odontologist if possible/ available. Record any that are absent, loose or damaged, and record all dental work (e.g. restorations, fillings) using a dental identification system to identify each tooth. Check the gums for periodontal disease. Photograph dentures, if any, and save them if the deceased's identity is unknown. Check the inside of the mouth and note any evidence of trauma, injection sites, needle marks or biting of the lips, cheeks or tongue. Note any articles or substances in the mouth. In cases of suspected sexual violence, save oral fluid, or get a swab for spermatozoa and acid phosphatase evaluation. (Swabs taken at the tooth-gum junction and samples from between the teeth provide the best specimens for identifying spermatozoa). Also take swabs from the oral cavity for seminal fluid typing. Dry the swabs quickly with cool, blown air

if possible, and secure them in clean plain-paper envelopes. (If rigor mortis prevents adequate examination, a complete oral examination may need to be deferred until later, during the internal examination. At that time, after subcutaneous dissection to expose the structures of the neck and face to permit better exposure of the oral cavity, the masseter muscles may be divided).

- Examine the face and note if lividity, congestion and/ or petechiae are present.
 - Examine the eyes and view the conjunctivae of both the globes and the eyelids. Note any petechiae in the upper or lower eyelids. Note any scleral icterus. Save contact lenses, if any are present. Collect at least 1 ml of vitreous humour from each eye.
 - Examine the nose and ears and note any evidence of trauma, haemorrhage, or other abnormalities. Examine the tympanic membranes.
- Examine all aspects of the neck externally and note any contusions, abrasions or petechiae. Describe and document injury patterns to help differentiate manual, ligature and hanging/ strangulation. Examine the neck at the conclusion of the autopsy (after removal of the brain and the thoracic contents), when the blood has drained out of the area, as this limits the formation of artefactual bruising associated with dissection.
- Examine all surfaces of the extremities – arms, forearms, wrists, hands, legs and feet – and note any “defence” wounds. Dissect and describe any injuries. Note any bruises about the wrists or ankles that may suggest restraints such as handcuffs or suspension. Examine the medial and lateral surfaces of the fingers, the anterior forearms and the backs of the knees for bruises.
- Note any broken or missing fingernails. Take fingerprints in all cases. (If it is not possible to have fingerprints taken, explore all possible avenues – e.g. removing the epidermal “glove” of the fingers, or keeping the body so that fingerprints can be taken in the following days – to avoid the unacceptable prospect of having to remove the fingers). Save fingernail clippings and any under-nail tissue (nail scrapings). Examine the fingernail and toenail beds for evidence of objects having been pushed beneath the nails. Nails can be removed by dissecting the lateral margins and proximal base, and then the under-surface of the nails can be inspected. If this is done, the hands must be photographed before and after this dissection. Carefully examine the soles of the feet, noting any evidence of beating. Incise the soles to delineate the extent of any injuries. Examine the palms and knees, looking especially for glass shards or lacerations.
- Examine the external genitalia and note the presence of any foreign material or semen. Note the size, location and number of any abrasions or contusions. Note any injury to the inner thighs or peri-anal area. Look for peri-anal burns.
- In cases of suspected sexual violence, examine all potentially involved orifices. A speculum should be used to examine the vaginal walls. Collect foreign hair by combing the pubic hair. Pull and save at least 20 of the deceased’s own pubic hairs, including roots. Aspirate fluid from the vagina and/ or rectum for analysis (e.g. acid phosphatase, blood group and spermatozoa). Take swabs from the same areas for seminal fluid typing. Dry the swabs quickly with cool, blown air if possible and secure them individually in clean plain-paper envelopes.
- The back, the buttocks and extremities including wrists and ankles must be dissected subcutaneously to look for deeper injuries. The shoulders, elbows, hips and knee joints must also be dissected subcutaneously, and possibly further, to look for ligamentous and related injury.

Current Practices in Autopsies to Rule out Sexual Violence

While conducting autopsies, doctors do not have any clear guidelines to check for sexual violence. In practice, doctors routinely comment on size of genital openings/ anus for all and provide detailed comments on secondary sexual characteristics in young girls.

Commenting on size of genital openings/ anus is unwarranted at autopsy and cannot be substantiated with scientific evidence (due to primary/ secondary relaxation of muscles, rigor mortis, decomposition)

and may lead to unnecessary comments. With progress in decomposition, external signs on genitals due to sexual violence gets deteriorated/ modified/ difficult to detect accurately.

The post-mortem changes on genitals due to decomposition may be misinterpreted as sexual violence, for instance post-mortem swelling, post-mortem oozing of secretions, bloating of genitals are often interpreted as sexual violence by some doctors leading to misleading investigation.

Internal Examination

The internal examination should clarify and augment the external examination in so far as injuries are concerned, and should identify and characterize any and all natural disease/s present. Remember to photograph the internal manifestations of injury and any other abnormalities identified. Ideally, photograph all organs and their cut surfaces. Before removing the organs, obtain fluid specimens such as blood, urine, and bile.

- Be systematic in the internal examination. Perform the examination either by body regions or by systems, including cardiovascular, respiratory, biliary, gastrointestinal, reticuloendothelial, genitourinary, endocrine, musculoskeletal and central nervous systems. Record the volume, colour, consistency and nature of any collections of fluid, and retain samples for further investigation if required. Record the weight, size, shape, colour and consistency of each organ, and note any neoplasia, inflammation, anomalies, haemorrhage, ischemia, infarcts, surgical procedures, or injuries. Take sections of normal and any abnormal areas of each organ for microscopic examination. Take samples of any fractured bones for further radiographic and microscopic estimation of the age of the fracture.
- Examine the chest. Note any abnormalities of the breasts. Record any rib fractures, noting whether cardiopulmonary resuscitation was attempted. Before opening the chest, check for pneumothorax. Record the thickness of subcutaneous fat. Immediately after opening the chest, evaluate the pleural cavities and the pericardial sac for the presence of blood or other fluid, and describe and quantify any fluid present. Save any fluid present until foreign objects are accounted for. Note the presence of air embolism, characterised by frothy blood within the right atrium and right ventricle. Trace any injuries before removing the organs. If blood is not available from other sites, collect a sample directly from the heart. Examine the heart, noting degree and location of coronary artery disease or other abnormalities. Examine the lungs, noting any abnormalities including the presence of blood or other material in the trachea and bronchi.
- Examine the abdomen and record the amount of subcutaneous fat. Note the interrelationships between the organs. Trace any injuries before removing the organs. Note any fluid or blood present in the peritoneal cavity, and save it until foreign objects have been accounted for.
- Remove, examine and record the quantitative information on the liver, spleen, pancreas, kidneys and adrenal glands. Remove the gastrointestinal tract and examine the contents. Note (and photograph) any food present and its degree of digestion. Save the contents of the stomach. If a more detailed toxicological evaluation is desired, the contents of other regions of the gastrointestinal tract may be saved. Examine the rectum and anus for burns, lacerations, or other injuries. Locate and retain any foreign bodies present. Examine the aorta, inferior vena cava and iliac vessels.
- Examine the organs in the pelvis, including ovaries, fallopian tubes, uterus, vagina, prostate gland, seminal vesicles, urethra, testes and urinary bladder. Trace any injuries before removing the organs. Remove these organs carefully so as not to injure them artefactually. Note any evidence of previous or current pregnancy, abortion/ miscarriage, or delivery, and any surgery. Save any foreign objects within the cervix, uterus, vagina, urethra, or rectum.

Guiding Principles in Autopsy Related to Victims of Sexual Violence

- The hymen is a poor marker of penetrative sexual activity or virginity in post pubertal girls.
- There is no place for virginity testing; it has no scientific validity and is humiliating for the individual.
- Digital examinations of the vagina and anus are rarely warranted. They should not be used to assess the tone or elasticity of the vagina or anus, or to comment on likelihood or frequency of penetration.
- Forensic specimens: the account of the assault will dictate whether and what specimens are collected. If in doubt, collect. Persistence of biological material is variable. It will be affected by time, activities (washing), decomposition and contamination from other sources. The forensic evidence collection must be scientific and the limitation of such evidence should be understood. It is likely to find evidence if specimens are collected within a time interval since the time of assault. These vary as follows:
 - skin including bite marks – 72 hours;
 - mouth – 12 hours;
 - vagina – up to 5 days;
 - anus – 48 hours;
 - foreign material on objects (condom/ clothing) – no time limit;
 - urine (toxicology) 50 mL – up to 5 days;
 - blood (toxicology) 2 × 5 mL samples – up to 48 hours in tubes containing sodium fluoride and potassium oxalate.

- Palpate the head and examine the external and internal surfaces of the scalp, noting any trauma or haemorrhage. Note any skull fractures. Remove the calvarium carefully and note epidural and subdural hematomas. Quantify, estimate the age, and save any hematomas present. Remove the dura to examine the internal surface of the skull for fractures. Remove the brain and note any abnormalities. (Preferably, retain the brain in fixative for some days prior to examination, if possible, with the assistance of a neuropathologist.) Dissect and describe any injuries. Cerebral cortical atrophy, whether focal or generalised, should be specifically commented upon.
- Evaluate the cerebral vessels and comment for thickening, injury, aneurysms, atheromatous plaques if any.
- Examine the neck after the thoracic organs and brain have been removed and the neck vessels have been drained. Remove the neck organs, including the tongue, under direct vision having reflected the skin of the front of the neck. Take care not to fracture the hyoid bone or thyroid cartilage. Dissect and describe any injuries. Check the mucosa of the larynx, pyriform sinuses and oesophagus, and note any petechiae, oedema, or burns caused by corrosive substances. Note any articles or substances within the lumina of these structures. Examine the thyroid gland. Separate and examine the parathyroid glands, if they are readily identifiable. Dissect the neck muscles, noting any haemorrhage.
- Dissect the muscles from, and note any fractures of, the hyoid bone or thyroid or cricoid cartilages. Consider also a posterior neck dissection if it is at all possible; there may be soft tissue or skeletal injuries there. Examine the cervical, thoracic and lumbar spine.
- Examine the vertebrae from their anterior aspects and note any fractures, dislocations, compressions or haemorrhages. Examine the vertebral bodies.
- In cases in which spinal injury is suspected, dissect and describe the spinal cord. Examine the cervical spine anteriorly and note any haemorrhage in the paravertebral muscles. The posterior approach is best for evaluating high cervical injuries. Open the spinal canal and remove the spinal cord. Make transverse sections every 0.5 cm and note any abnormalities.

Further Testing

After the autopsy has been completed, saved specimens must be recorded and listed in the report. Label all specimens with the name of the deceased, the autopsy identification number, the date and time of collection, the name of the doctor (if applicable), and the contents.

Carefully secure all evidence and begin the chain of custody record with the appropriate release forms. There should be agreement with the investigating officer about how the samples will be stored and then transported to the laboratory undertaking the analysis. The transport of such samples is usually a police responsibility exercised following full chain of custody requirements which ensure the security of the samples.

- **Large organ and tissue specimens:** Sometimes large organ and tissue specimens may be retained by the forensic doctor for:
 - Better examination of an organ of particular importance in the case (e.g. the brain).
 - Further examination by an expert.
 - Use as direct evidence.

Documentation of authorisation is a must. The next of kin should be informed about the retention of organs/ tissues/ foetus obtained.

- **Histology/ Histopathology:** In all cases of potentially unlawful death, small representative samples of all major organs, including areas of normal and any abnormal tissue, should be retained in 10 percent formalin, processed histologically and stained with hematoxylin and eosin (and other stains as indicated). The wet tissue, paraffin blocks and slides should be kept indefinitely. Many forensic doctors are not trained to evaluate histology material. Arrangements should be made for a suitable histopathologist, preferably one with forensic training and experience, to report on the histology. This should be done in consultation: the histopathologist needs to understand the history and findings from the autopsy; and the forensic doctor needs to understand the conclusions, and any limitations, of the histopathologist.
- **Toxicology (including biochemistry):** Communication with the testing laboratory is very important. The fluids and volumes required, and the tissue required (if any), will vary from laboratory to laboratory. In all cases, the site from which the specimen has been obtained must be carefully recorded.
 - **Blood:** If possible, at least 10 ml, preferably obtained from a peripheral site (e.g. the femoral vein) prior to the commencement of the autopsy. To avoid post-collection fermentation and putrefaction, add 1 percent w/v sodium fluoride (NaF) to the collection tube. If peripheral blood is not available, a central site (e.g. the heart) can be used. As a last resort, blood from a body cavity can be obtained, although this will almost certainly be contaminated owing to leakage from other structures (e.g. stomach or bowel contents, mucus, urine, pus or serous fluids) and thus the interpretation of the results will be seriously compromised.
 - **Urine:** If possible, at least 10 ml is usually obtained by direct needle puncture of the exposed bladder after the abdomen has been opened. Alternatively, a urinary catheter inserted via the urethra can be used.
 - **Vitreous Humour:** 2–3 ml can be obtained by needle puncture of each globe. As it is relatively viscous, a 15- or 17-gauge needle should be used.
 - **Bile:** Up to 10 ml.
 - **Tissue:** Liver, muscle, kidney, brain, adipose tissue (if possible, 100 mg of each), skin site (e.g. if an insulin injection is suspected). The tissues should be placed in separate, clean, glass or plastic jars without a fixative. Consider freezing the samples if delays are anticipated before transport to the laboratory, or before analysis. If volatile substance inhalation is suspected, an

entire lung should be taken and sealed in a nylon bag. (Polyethylene/ plastic bags are permeable to volatile substances).

- **Stomach contents:** Ideally, prior to removing the abdominal contents, the stomach can be isolated by clamping or tying the lower oesophagus and duodenum. After removal, the stomach should be opened inside a large clean dish. After describing and photographing the contents, submit them in secure, clean, screw-top glass or plastic jars.
- **Hair and fingernails:** These may be useful in cases of heavy-metal poisoning or certain drugs. Obtain hair samples by plucking the hair, thereby including the root; do not cut with scissors. Nail samples should comprise the whole nail.
- **Microbiology:** This is not a routine autopsy investigation but can be useful if the collection technique is good and samples are collected in the early post-mortem period. Differentiating between pathogens and normal post-mortem flora complicates the assessment of results. Possible samples include:
 - Blood, taken using a sterile needle and syringe under direct vision from the femoral vein or artery (or other suitable vessel), accessed in a sterile manner prior to commencing the autopsy.
 - Sampling a small piece of tissue (e.g. lung, spleen) under conditions that are as sterile as possible.

The specimen should be taken to the microbiology laboratory without undue delay. Otherwise, the specimen should be kept in a refrigerator until (the earliest possible) transfer.

- **Entomology:** The collection of appropriate samples of larvae, beetles, flies and other insects on or in the body requires consultation with an entomologist. This includes eggs, maggots and pupae as well as adult insects. Samples may be useful for toxicological analysis as well as helping to assess the minimum post-mortem interval and/ or possibly to assess whether the body has been moved some distance after death. States must develop a protocol for chain of custody of entomology samples. In India, forensic entomology is a developing field. Efforts to bridge this gap by use of entomology division of agricultural universities can be attempted with its own limitations (forensic and legal interpretations/ value) on identifying the species of flies, life cycle, life span, habitat, environmental conditions. But the forensic science laboratories can still detect poisoning by chemicals and drugs with the analysis of flies/ extract.
- **Molecular/ DNA testing:** This is a rapidly developing technological area. The importance of liaising with the relevant laboratory cannot be overemphasized. Splenic tissue is one of the best organs for DNA recovery, although liver, muscle, kidney and brain tissue may also be used. At least 2g of tissue should be placed in a plastic tube without fixative or preservative. The specimen may then be frozen if it is not to be used immediately. In the case of decomposed or skeletonized remains, a sample of bone may be submitted, often the mid shaft of the long bones or teeth (without reparation or cavity), or part of the shaft of the femur. Techniques using less invasive samples such as cartilage, phalanges, fingernails, or toenails have been developed in some centres.
- **In addition,** other evidence that may need to be collected, recorded and secured includes:
 - All foreign objects, including projectiles, projectile fragments, pellets, knives and fibres. Projectiles must be subjected to ballistic analysis.
 - All clothes and personal effects of the deceased, either worn by or in the possession of the deceased at the time of death.
 - Fingernails and under-nail scrapings.
 - Hair, foreign and pubic, in cases of suspected sexual violence.
 - Head hair, in cases where the place of death or location of the body prior to its discovery may be an issue.
 - Bullets extracted from the bodies of victims must be preserved.

After the autopsy, all organs not retained should be replaced in the body, and the body should be well reconstructed/ preserved to facilitate a second autopsy in case one is desired at some future point. Cremation of the remains will of course prevent a second autopsy.

Concluding the Cause of Death

At the end of autopsy, it is the responsibility of the doctor to conclude the cause of death and identification of the deceased. But in many cases, cause of death cannot be determined from the autopsy findings alone without any other information/ investigation/ laboratory tests about the death. Often, the doctor is also required to conclude the manner of death. But the final authority is the court when it comes to concluding the death investigation.

The internationally accepted format for recording the cause of death is set out by the World Health Organization (WHO) in "The International Form of Medical Certificate of Cause of Death."²⁰

The part of the form on cause of death includes the following sections:

Part I – includes diseases or conditions directly leading to death (immediate causes) and antecedent causes (or underlying causes).

Part II – other significant conditions contributing to death, but not contributing to or causing the conditions listed in Part I.

All doctors should clearly understand the concepts involved in correctly concluding the cause of death according to the standard WHO format. The report and other documents should be handed over in sealed envelopes to the Investigating Officer.

The autopsy report

The autopsy report should be sufficiently comprehensive for another forensic doctor, at another time and place (and supported by access to the photographs) to be in possession of all the relevant observations required in order to come to his or her own conclusions about the death.

At the end of the autopsy, report should be a summary of the findings, including the results of special tests. In addition, the doctor should provide his/ her opinion about the identity of the deceased, injuries and diseases present, attributing any injuries to external trauma, therapeutic efforts, post-mortem change, or other ante-mortem, peri-mortem, or post-mortem causes.

Opinion as to how the injuries might have been caused, and whether they caused or contributed to death, should be provided. Reasonable, evidence-based conclusions about the circumstances of the death (including where appropriate the manner of death) should be made. Finally, the formal cause of death, as discussed above, should be provided and explained. The full report should be given to the appropriate authorities (except if they are implicated in the cause of the death) and to the deceased's next of kin.

Autopsy Signs of Possible Torture

The table below mentions the forms of torture that are known to be used. The purpose is not to match the findings or consequences but be aware of the various ways of torture. The health professional should document the findings and not evaluate whether the findings are typical or diagnostic of trauma.

TORTURE TECHNIQUE	PHYSICAL FINDINGS AND NOTES ON THEIR DETECTION
Acute (single episode) and chronic (repeated episodes of) injury	Abrasions, bruises, lacerations, scars; fractures (and, if multiple, some at different stages of healing), especially in unusual locations, which have not been treated. Skull fractures, scalp bruising, laceration, cerebral contusions and other intracranial manifestations of trauma; after time, cerebral cortical scars and atrophy.

²⁰ World Health Organization. (1979). *Medical certification of cause of death: instructions for physicians on use of international form of medical certificate of cause of death* (4th ed.). Geneva: World Health Organization. Retrieved from <http://www.who.int/iris/handle/10665/40557>

	<p>Consider cervical spine trauma when facial trauma present Assess nasal bone alignment, crepitation, deviation of the septum; consider plain X-ray, CT scan for the septum. Assess for rhinorrhoea and orbital plate/ crista galli fracture.</p> <p>Consider fractures of the temporo-mandibular and laryngeal structures. Assess these as part of a detailed neck and facial examination following subcutaneous dissection. At the same time also look for tooth avulsions and fractures; dislocated dental fillings; broken dental prosthesis; bruised tongue; lesions from forcible insertion of objects into the mouth, electric shocks or burns.</p> <p>Specific injuries may disclose a shape suggestive of the causative object, e.g. tramline bruising from rods, truncheons or canes.</p> <p>Consequences of blunt force injuries to the orbit, including “blow out” fractures (and/ or loss of integrity of the globe), conjunctival haemorrhage, lens dislocation, sub hyaloid haemorrhage, retrobulbar haemorrhage, retinal haemorrhage.</p>
Suspension by the wrists (“La bandera”)	Bruises or scars around the wrists. A chronic linear zone around a wrist or ankle, with few hairs or follicles, is most likely to be a cicatricial alopecia from the prolonged application of a tight ligature. There is no differential diagnosis of spontaneous skin disease for such an appearance.
Suspension by the neck or arms (e.g., “cross suspension” – spreading the arms and tying them to a horizontal bar; “butchery” – tying the hands upwards together, or one by one)	Bruising or scars at the site of binding; prominent lividity in lower extremities; neck trauma (often minimal but may include fractures to larynx).
Suspension with the feet upwards and head downwards (“reverse butchery”, “murciélago”)	Bruises or scars around the ankles; ligamentous damage, dislocations to ankles or other joints.
Suspension from a ligature tied around the elbows or wrists with the arms behind the back; or the forearms bound together behind the back with the elbows flexed to 90 degrees and the forearms tied to a horizontal bar (“Palestinian hanging”)	Abrasions, bruises, scars around the wrist(s); dislocation of shoulder joint, or ligamentous damage, muscular tears and/ or necrosis to upper arm or pectoral muscles; myoglobinuric renal damage or failure.
Suspension of a victim by the flexed knees from a bar passed below the popliteal region, usually while the wrists are tied to the ankles (“parrot perch”, “Jack”, “pau de arara”) (can lead to cruciate ligament tears)	Abrasions, bruises, and/ or lacerations, scars on the anterior forearms and backs of the knees; abrasions, bruises to the wrists and/ or ankles.
Forcible immersions of head in water often contaminated with urine, feces, vomit or other impurities (“wet submarine”, “pileta”, “latina”)	Signs of drowning/ near drowning; fecal or other debris in the mouth, pharynx, trachea, oesophagus or lungs.
Many other forms of positional torture, tying or restraining victims in contorted, hyperextended or other unnatural positions.	Fractures, dislocations, injuries to ligaments, tendons, nerves and blood vessels, both recent and old.

Blunt abdominal trauma while lying on a table with the upper half of the body unsupported (“operating table”, “el quirófano”)	Abdominal bruises, back injuries, injuries to abdominal viscera including rupture. Intramuscular, retroperitoneal, intra-abdominal haemorrhage
Hard slap of palm to one or both ears (“teléfono”)	Rapid increase of pressure in ear canals causes ruptured ear drum(s); after time, these will appear scarred. There may be injuries to the external ear. Use otoscope
Whipping	Multiple depigmented, linear hypertrophic scars surrounded by a zone of hyperpigmentation are most likely the consequence of whipping. Exclude plant dermatitis or false bruise or pseudo bruise.
Forcible removal of a fingernail or toenail	Acute laceration and bruising to the nail bed and skin of the distal phalanx; other injuries associated with restraint. Later, an overgrowth of tissue may be produced at the nail fold forming a pterygium. Lichen planus is the relevant differential diagnosis, and this is usually accompanied by other skin lesions. Fungal infections produce thickened yellowish crumbling nails.
Burns	Cigarette, hot objects acutely result in characteristic burns (after time, these cause atrophic scars with narrow hypertrophic and hyper-pigmented periphery. Spontaneously occurring inflammatory processes lack this characteristic marginal zone); when the nail matrix is burnt, subsequent growth produces striped thin deformed nails, sometimes broken up in longitudinal segments.
Electric shock (wires connected to a source of electricity; e.g. “cattle prod”/ “la picana”: pointed electric instrument, metal on the tip)	Electric shock to hands, feet, fingers, toes, ears, nipples, mouth, lips or genitalia. Gels or water often used to prevent detectable burns. The appearance is of burns and depends upon the age of the injury. Immediately: red spots, vesicles and/ or black exudate. Within a few weeks: circular reddish macular scars. At several months: small, white, reddish or brown or hyperpigmented spots (picana).
Heated metal skewer inserted into the anus (“black slave”)	Peri-anal or rectal burns
Repeated blunt trauma to the soles of the feet (and occasionally the hands or hips) (“falanga”, “falaka”, “bastinado”)	May be missed on cursory external examination; even if signs are present, swelling and not bruising may be the dominant appearance. Closed compartment syndrome may lead to muscle necrosis (aseptic), or vascular compromise of toes or even the distal foot. Fractures of carpal and metatarsals can occur. The aponeurosis and tendons may be torn. After time, irregular scars involving the skin may occur.
Sexual violence	Sexually transmitted disease; pregnancy; injuries to the breasts or genitalia. All the signs of penetration of vagina, anus or mouth and their differential diagnoses.

Table Indicative of Type of Evidence to be Collected in Sexual Violence²¹

History of Sexual Violence	Type of Swab	Purpose	Points to Consider
Peno-vaginal	Vaginal swabs	- Semen/ sperm detection - Lubricant - DNA	Whether ejaculation occurred inside vagina or outside Use of condom
	Body swabs	- Semen/ sperm detection - Saliva (in case of sucking/ licking)	If ejaculation occurred outside
Peno-anal	Anal swabs	- Semen/ sperm detection - DNA - Lubricant - Faecal matter	Whether ejaculation occurred inside anus or outside Use of condom
	Body swabs	- Semen/sperm detection - Saliva (in case of sucking/licking)	If ejaculation occurred outside
Peno-oral	Oral swabs	- Semen/ sperm detection - DNA - Saliva	Whether ejaculation occurred inside mouth or outside Use of condom
	Body swabs	- Semen/ sperm detection - Saliva (in case of sucking/ licking)	If ejaculation occurred outside
Use of objects	Swab of the orifice (anal, vaginal and/ or oral)	Lubricant	Detection of lubricant used if any
Use of body parts (fingering)	Swab of the orifice (anal, vaginal and/ or oral)	Lubricant	Detection of lubricant used if any
Masturbation	Swab of orifice/ body part	-Semen/ sperm detection -DNA -Lubricant	Whether ejaculation occurred or not If ejaculated in orifice or body parts

²¹ *Guidelines and Protocols for medico-legal care for survivors/ victims of Sexual Violence*, annexure 4, Page 59.

Audit Sheet

Documentation done

Procedure	Yes	No
Proper authority obtained/ request for PM		
Scene visit		
Photography of the body & videography		
Radiography		
Nail scraping		
Proper dissection of injured area/ affected part		
Natural orifices Detail examination Nose (hair pulling/ infection) Ears (Infection, tympanic membrane rupture, bleeding) Mouth (Gingival hygiene, caries, fracture & extraction of teeth, swabs for semen, STD) Anus (recent injuries) Vagina (recent injuries, sexual acts, STDs, Semen)		
Toxicology screening		
Relevant medico-legal issues addressed (answer to the questions of Inquiring Officer addressed)		
Documentation done		

Annexure 1

MODEL POST-MORTEM REPORT FORM

(Modified & adapted from Minnesota Protocol & National Human Rights Commission, India model form)

(Post mortem report should preferably be typed or computer-generated printout)

NAME OF INSTITUTION -----
Post Mortem Report No.-----
Date on Conducted by Doctor -----
Date & Time of receipt of the body &
Inquest papers for Autopsy-----
Date & Time of commencement of Autopsy -----
Date & Time of Completion of Autopsy -----
Date & time of examination of the dead body at
Inquest (as per Inquest Report) -----
(In alleged encounter deaths, it may be done in a scientific manner along with still photography).

CASE PARTICULARS

- 1 (a) Name of deceased (as entered in the Jail or Police
record or other records) -----
(b) S/0, D/0, W/0 -----
(C) Address -----
-
- 2 Age (Approx): ----- years Sex – Male/ Female/ Other
- 3 Body brought by (Name and rank of Police officials)
 - i. -----
 - ii. ----- of Police Station
- 4 Body identified by (Names & addresses of relatives/ persons acquainted)
 - i. -----
 - ii. -----
- 5 If Death occurred in Hospital (particulars as per hospital records)
 - i. Date & Time of Admission in Hospital -----
 - ii. Date & Time of Death in Hospital -----
 - iii. Central Registration Number of Hospital -----
- 6 Alleged History (in brief, as per Inquest papers)

7 SCHEDULE OF OBSERVATIONS

(A) GENERAL

(1) Length -----cms. (2) Weight -----Kgs.

(3) Physique - (a) Lean/ Medium/ Obese

(b) Well-built/ Average built/ Poor built/ Emaciated

(4) Identification features (if body is unidentified)

i. -----

ii, -----

iii Finger prints to be taken on a separate sheet & attached by doctor

(5) Description of clothes worn - important features:

(6) Post-mortem Changes:

- Eye changes -
- PM Staining/ lividity
- Rigor mortis (if present, the extent)
- Decomposition changes (if any)

(7) External appearance

(a) Natural orifice

(Mouth, Nose, Ears)

(b) Nails

(c) Any other

(B) EXTERNAL INJURIES

Instructions -

- i. Mention type, Shape, Length, Breadth & Depth of each injury and its relation to important body landmark.
- ii. Indicate which injuries are fresh and which are old and their duration.
- iii. Injuries be given serial number & mark similarly on diagrams attached
- iv. In stab injuries mention angles, margins and direction inside body
- v. In firearm injuries mention the effect of fire also

(C) INTERNAL INJURIES

1. HEAD

(a) Scalp findings

(b) Skull (Describe fractures here & show them on body diagram enclosed)

(c) Meninges, Meningeal spaces & cerebral vessels (haemorrhage & its locations)

(d) Brain findings and weight

(e) Any other

2. NECK

- Mouth, Tongue & Pharynx
- Larynx & Vocal cords
- Condition of neck tissues
- Thyroid & other cartilages
- Any other

3. CHEST

- Ribs & chest wall
- Oesophagus
- Trachea & bronchial tree
- Diaphragm
- Pleura – Right
- Pleura – Left
- Lung weight Right.....grams, Left.....grams
- Lung findings
- Pericardial sac
- Heart findings & weight
- Large blood vessels
- Any other

4. ABDOMEN

- Condition of abdominal wall
- Peritoneum & peritoneal cavity
- Stomach weight Grams

- Stomach wall condition, contents & smell
 - Small intestines including appendix
 - Large intestines & Mesenteric vessels
 - Liver weight
 - Liver findings including gall bladder
 - Spleen findings & weight Grams
 - Pancreas
 - Kidney weight Right grams, Left grams
 - Kidney findings
 - Bladder & Urethra
 - Pelvic cavity
 - Pelvic bones
 - Genital organs (Note the condition of vulva, vagina, penis, scrotum, clitoropenis, labioscrotum, presence of foreign . body, presence of foetus, semen or any other fluid, and contusion, abrasion in and around genital organs)
 - Any other
5. SPINAL COLUMN & SPINAL CORD (to be opened where indicated)

6. ADDITIONAL REMARKS IF ANY

OPINION

1. Probable time since death (keep all factors including observation at inquest)
2. Cause of death – The cause of death to the best of my knowledge and belief is
 - (a) Immediate cause
 - (b) Due to
 - (c) Which of the injuries are antemortem/ postmortem and duration if antemortem?

(d) Manner of causation of injuries

(e) Whether injuries (individually or collectively) are sufficient to cause death in ordinary course of nature or not?

3. Any other

Annexure 2

SPECIMENS COLLECTED AND HANDED OVER (please tick)

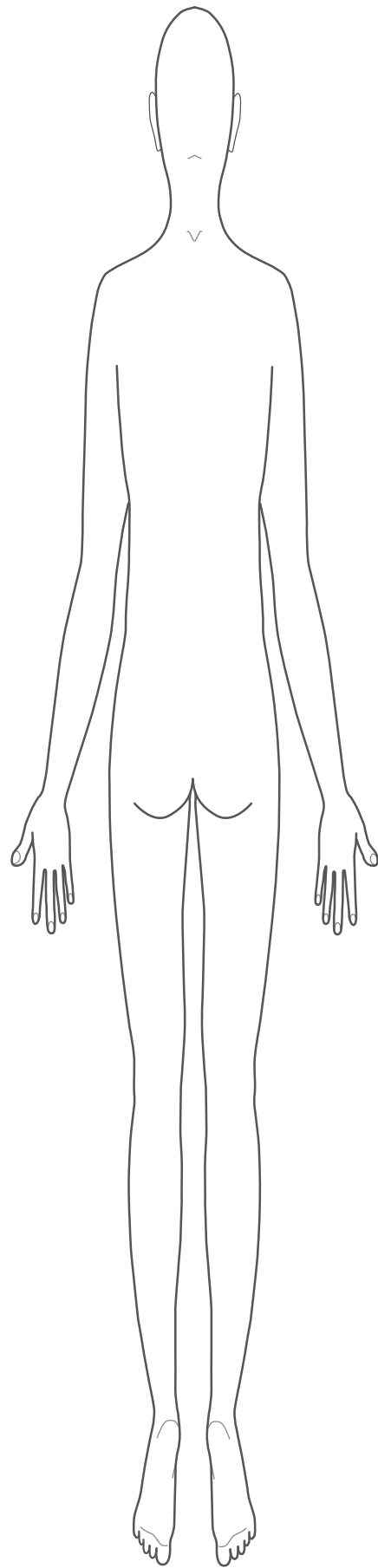
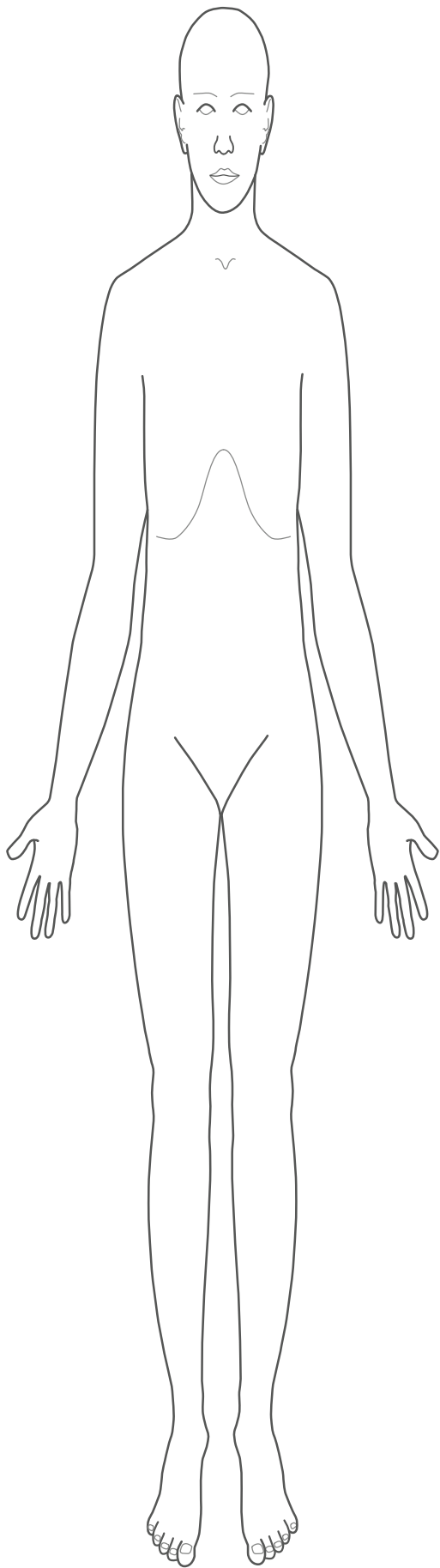
- i) Viscera (Stomach with contents, small intestine with contents, sample of liver — 500 grams. kidney (one half of each), spleen, Blood (up to 100 ml.), sample of blood on gauze piece (air dried), vacutainers, any other viscera, preservative used for chemical/ Toxicological analysis
- ii) Specimen collected for Histopathological examination (mention name of organs/ tissues)
- iii) Body fluids, secretions in culture media or appropriate medium for microbiological and/ or Immunological examination and/ or Biochemical examination
- iv) Clothes
- v) Photographs (Video cassettes in case of custody deaths), finger prints etc.
- vi) Foreign objects (like bullet, ligature etc)
- vii) Slides from vagina, semen & other material, if any
- viii) Any other
- ix) Any other
- x) Sample seal with specimen signatures
- xi) Inquest papers (mention total number and initial them)

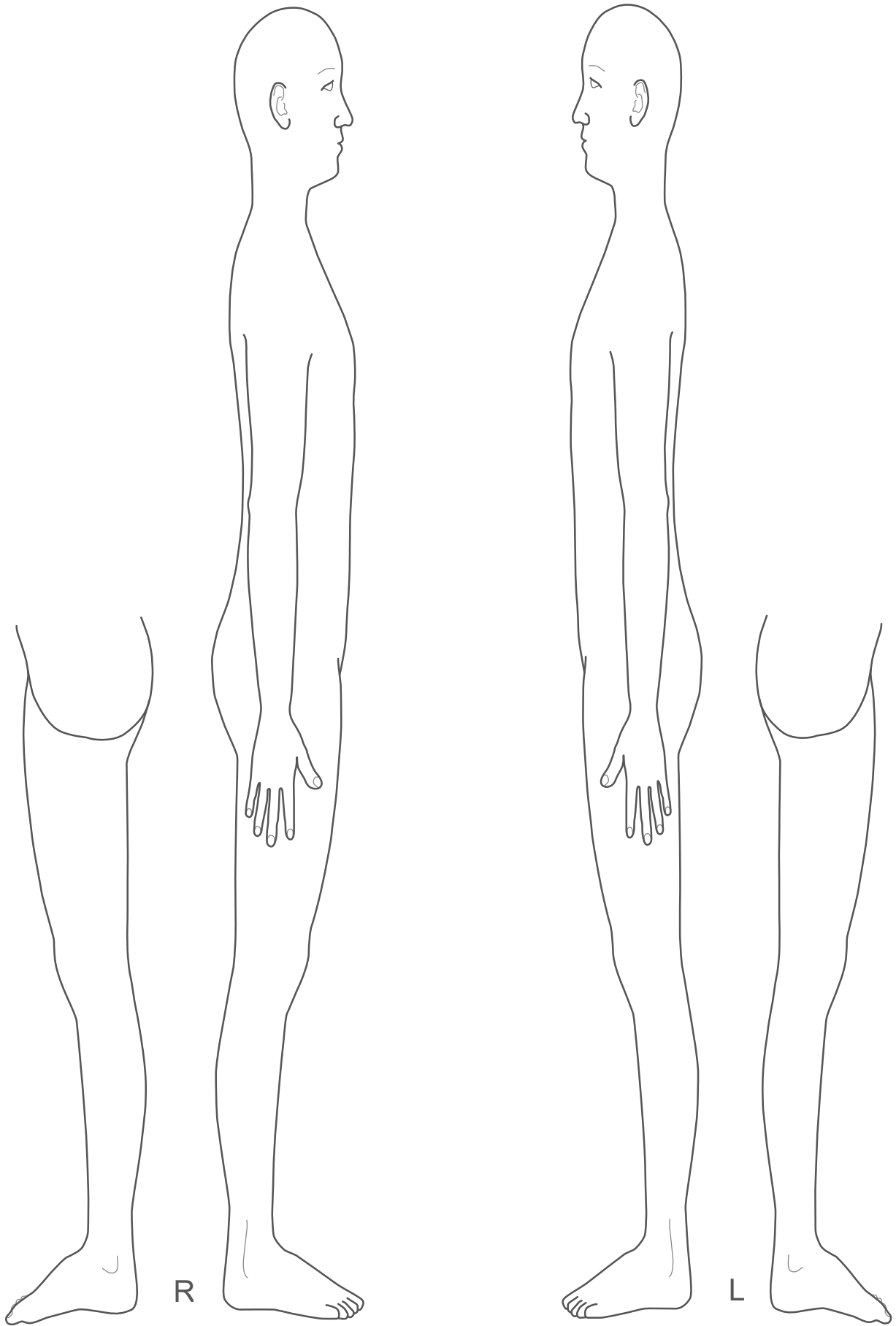
PM report in original, ----- inquest papers, dead body, clothings & other articles which are duly packed, sealed and labelled numbers, handed over to police official number of police station whose signatures are herewith.

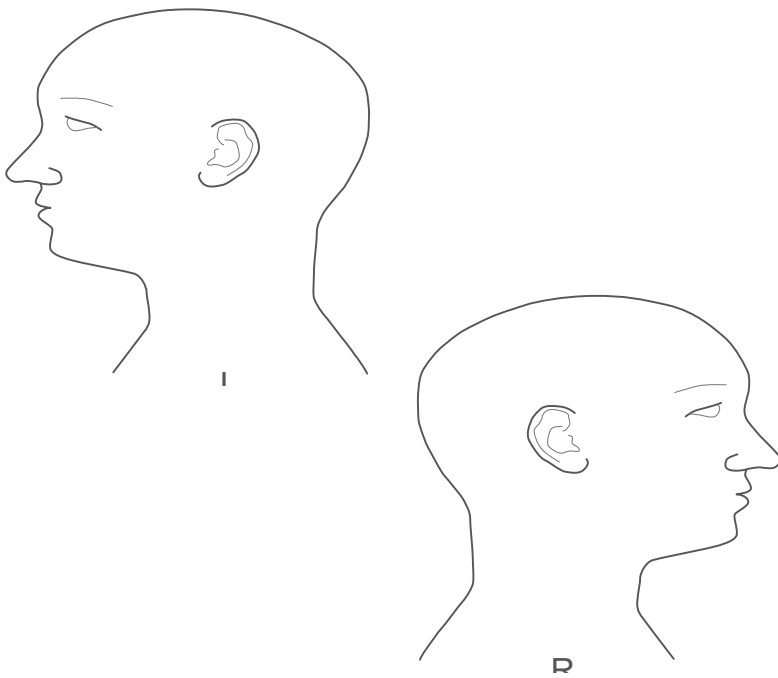
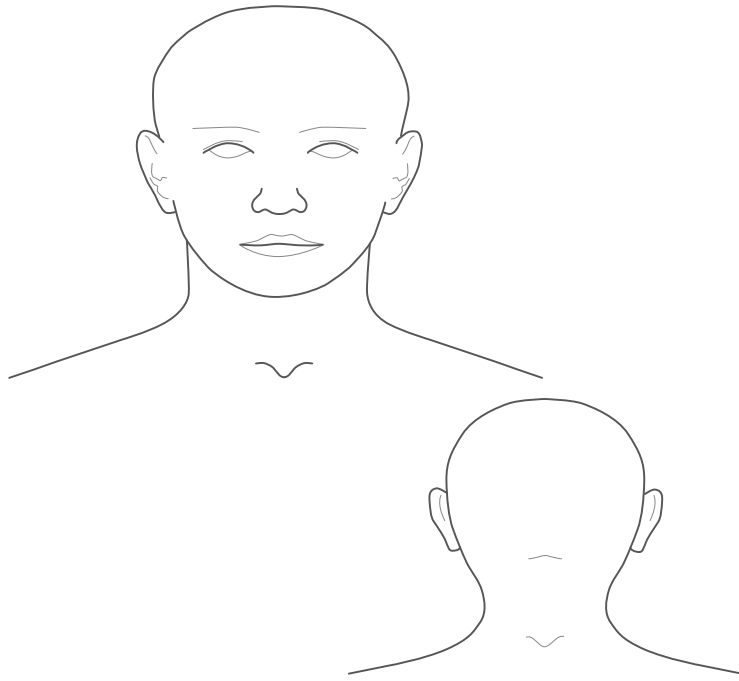
Signature
Name of Medical officer
Designation
Seal


Receiving by Investigating Officer

Signature
Name
Rank
Belt number
Police station
Date of collection







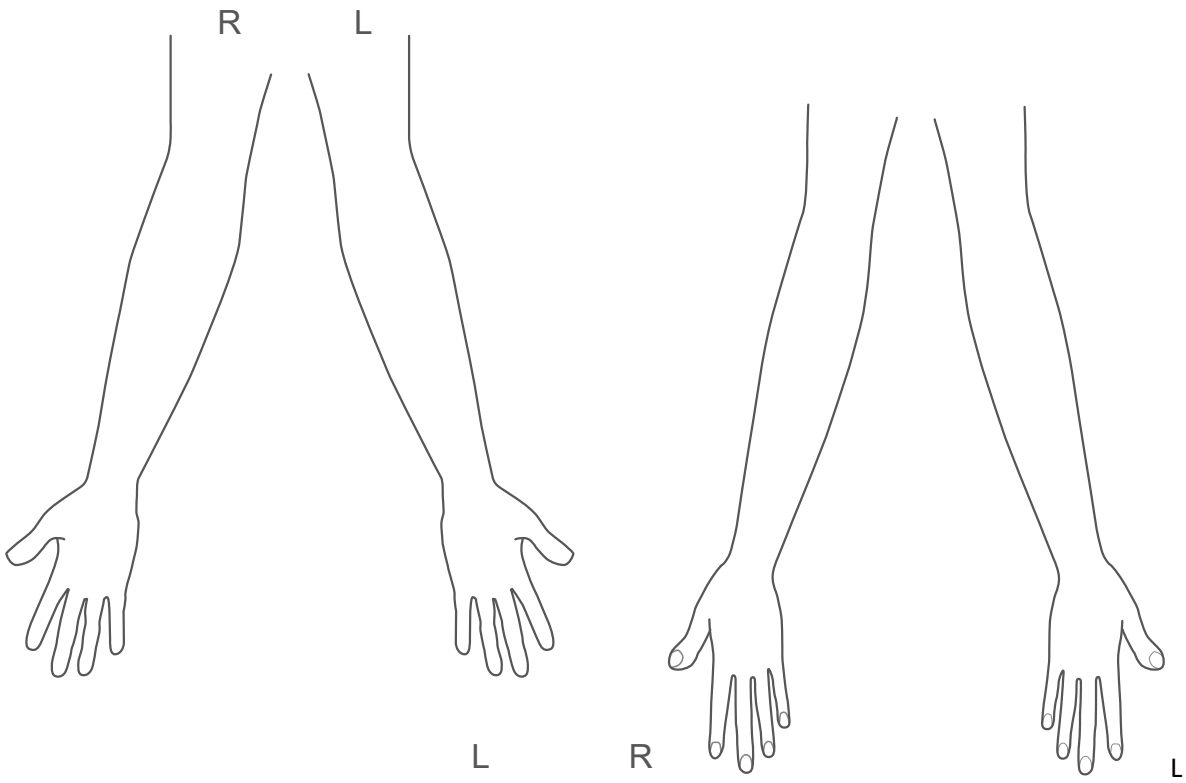


L

R

L

R



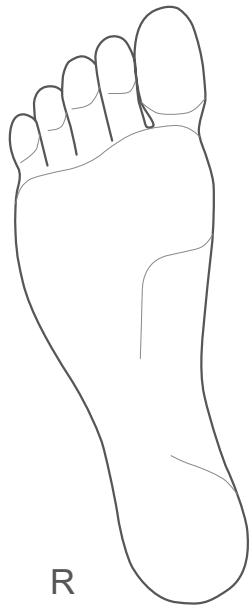
R

L

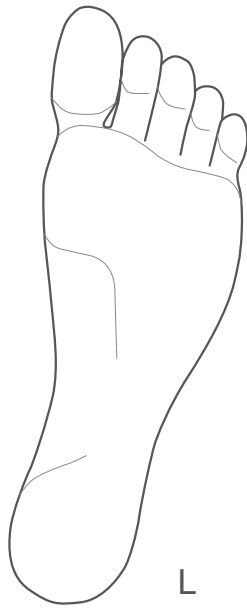L

R

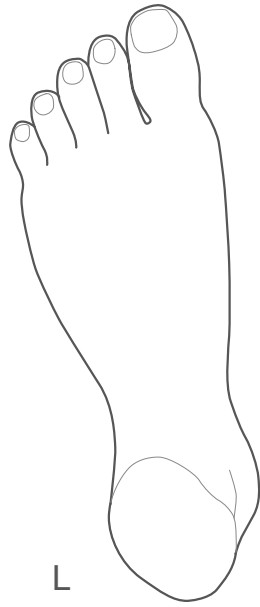
L



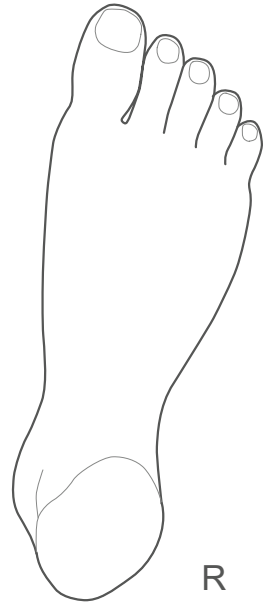
R



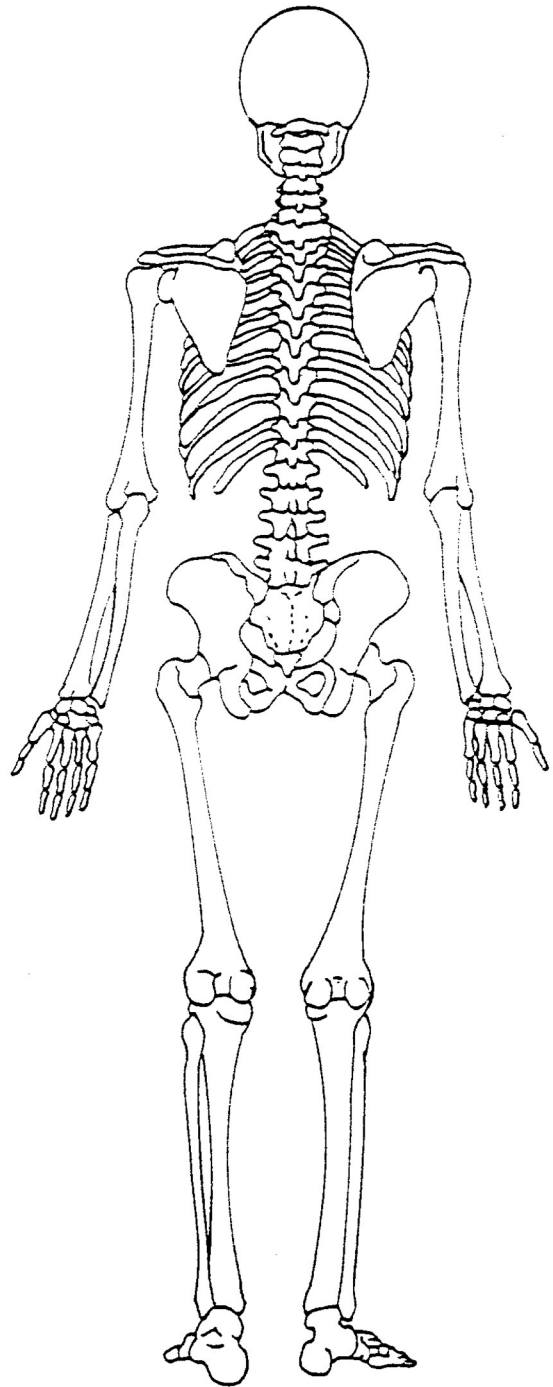
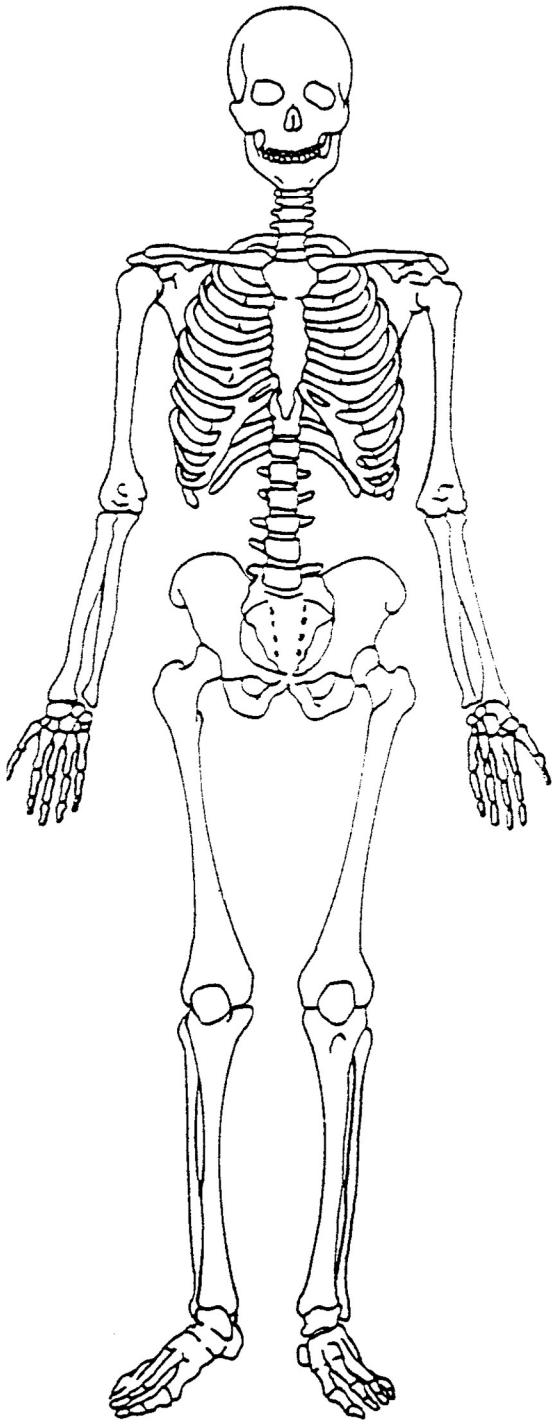
L

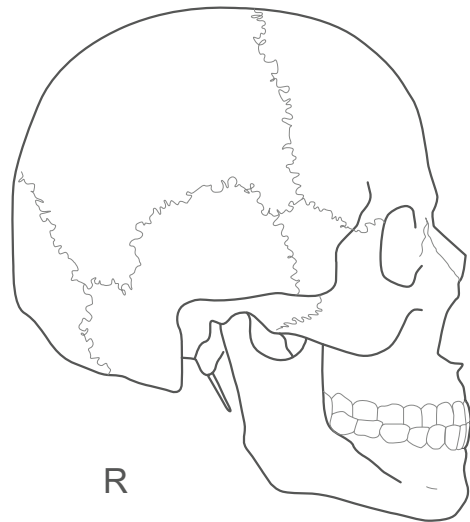
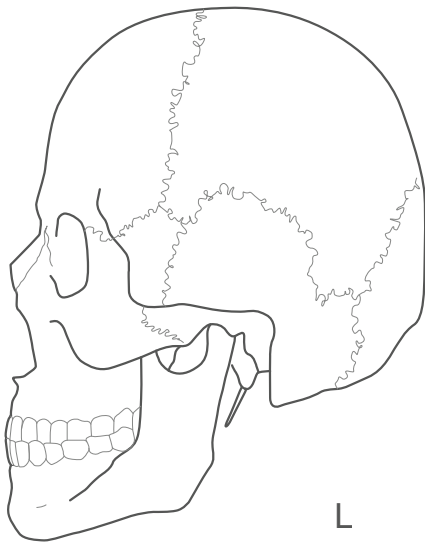
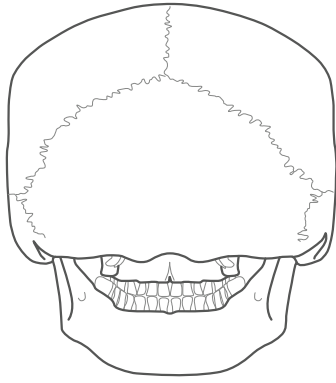
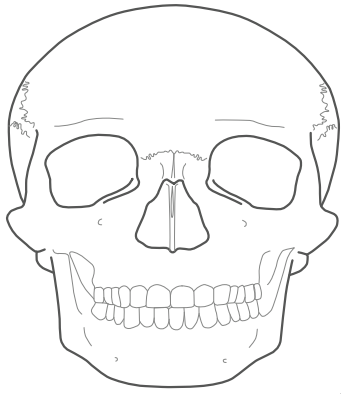


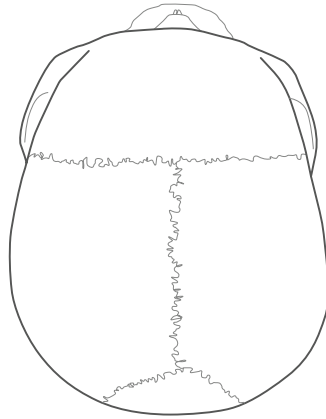
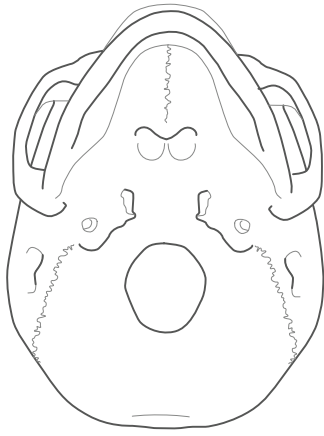
L



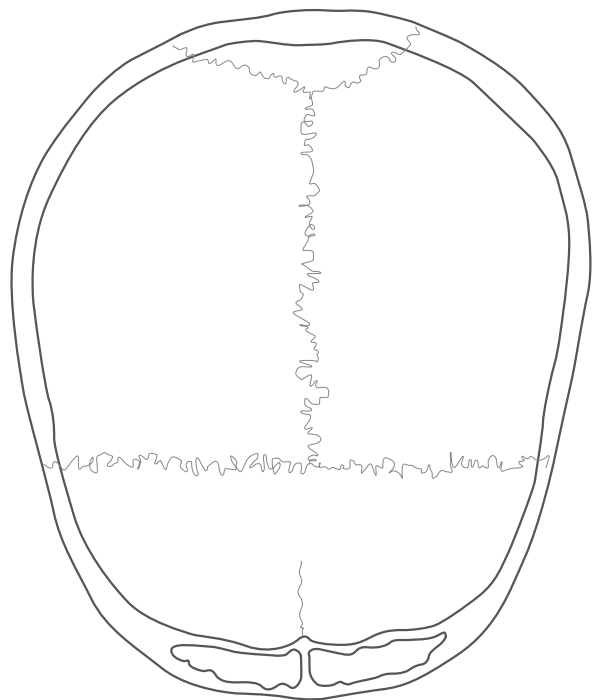
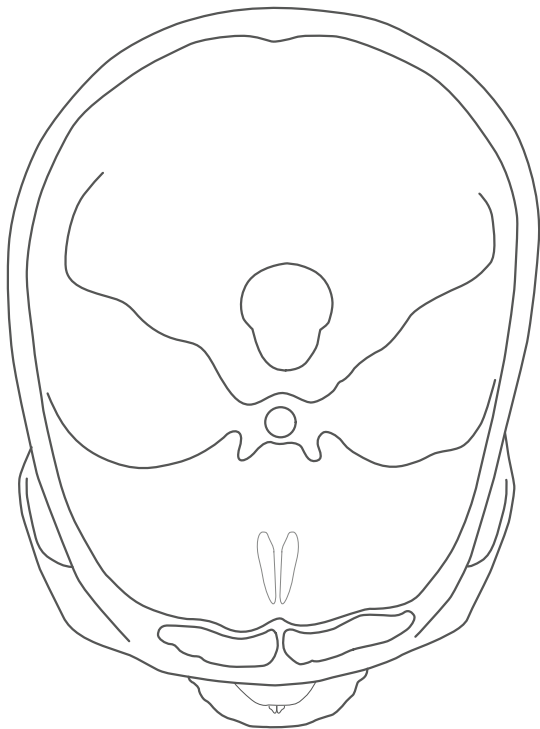
R

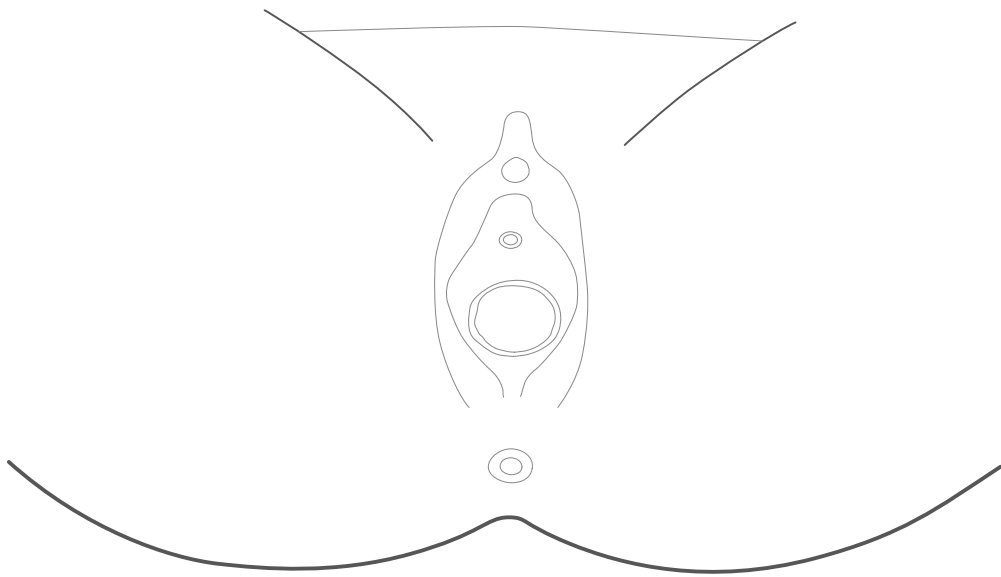
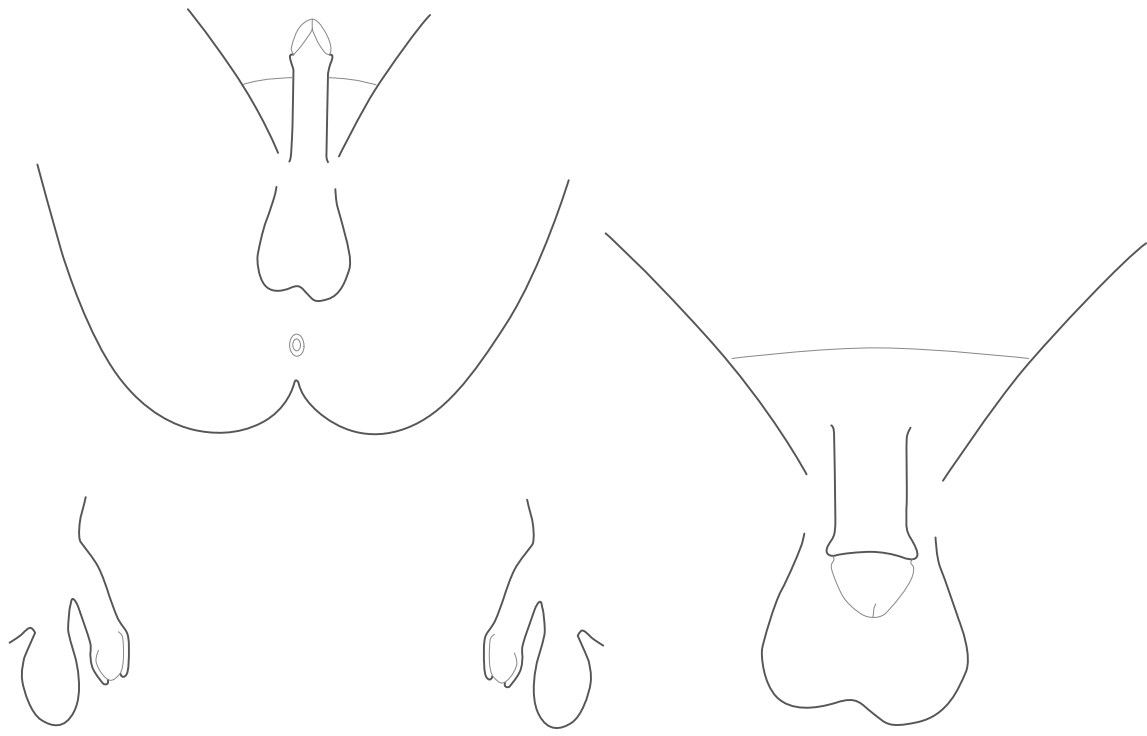


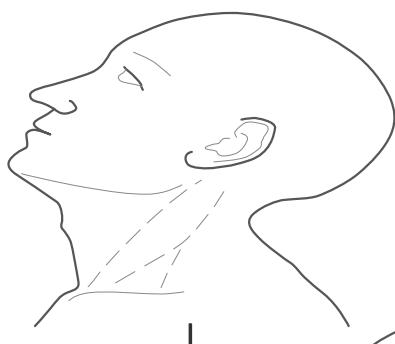
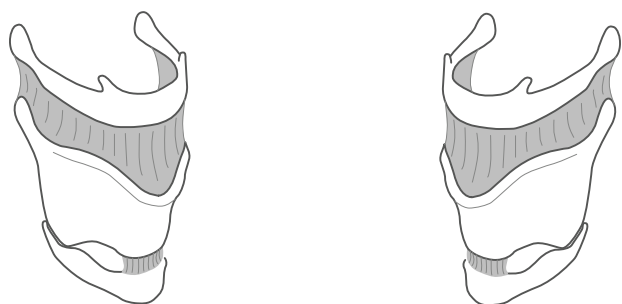
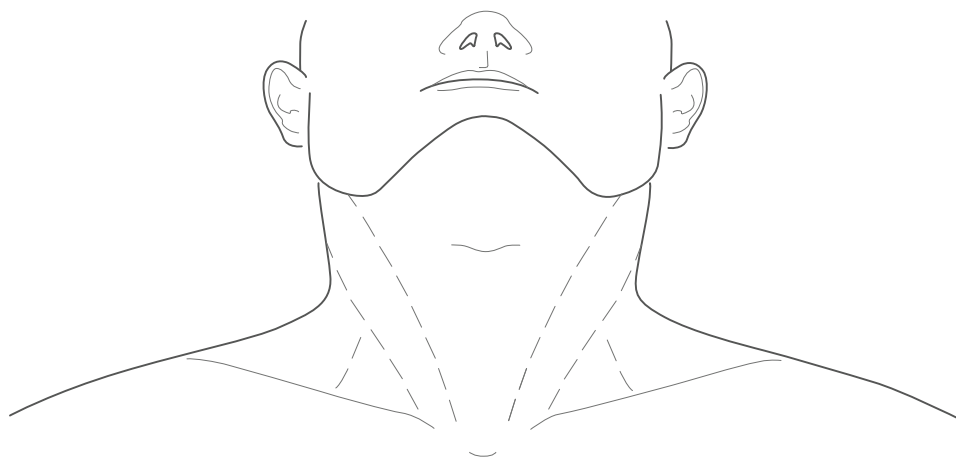




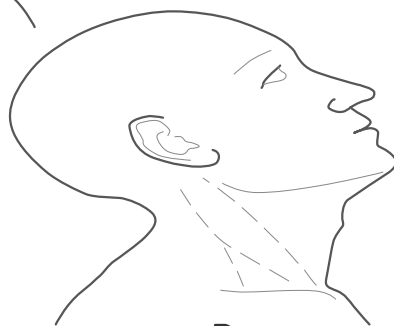2



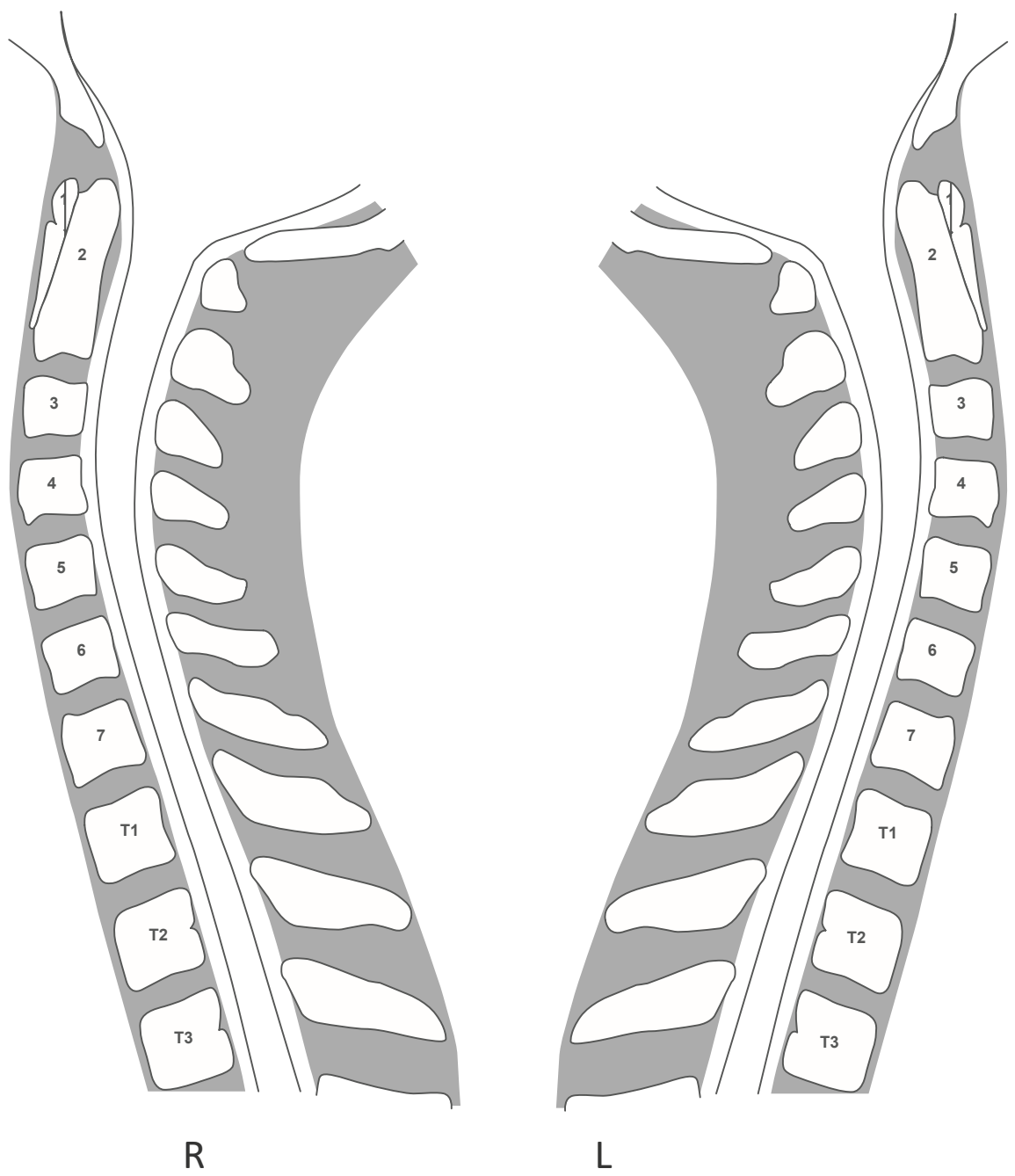


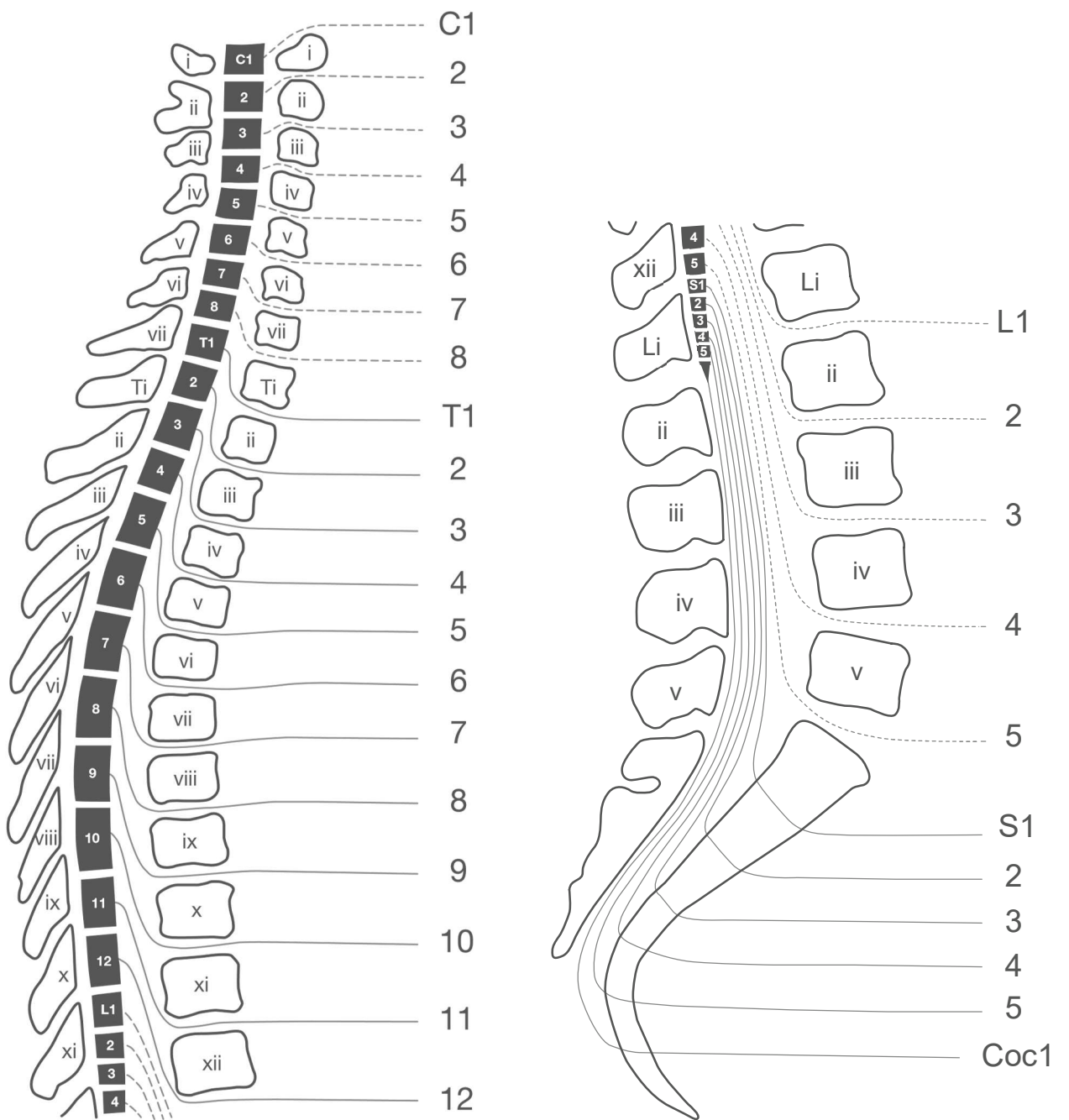


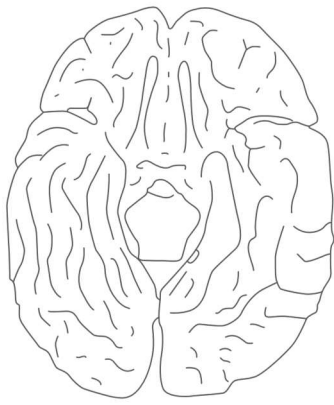
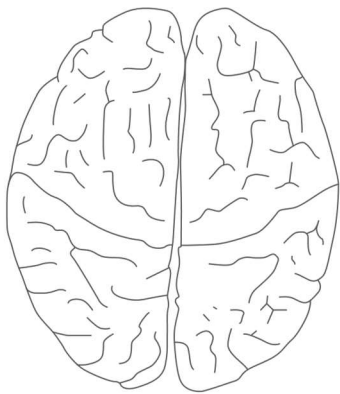
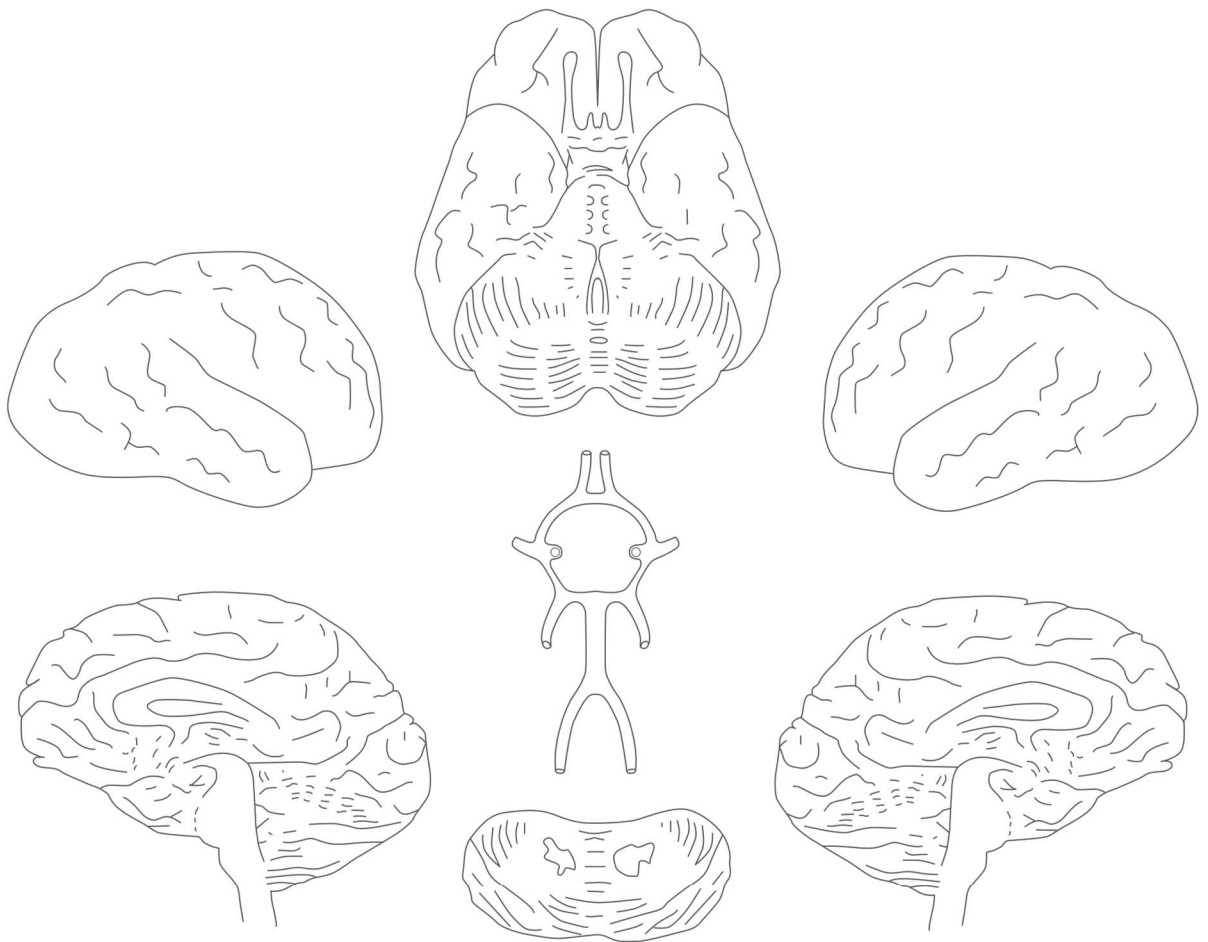
L



R

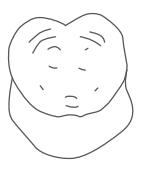




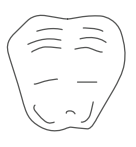
C
T
L
R
S

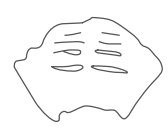L



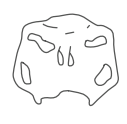midbrain



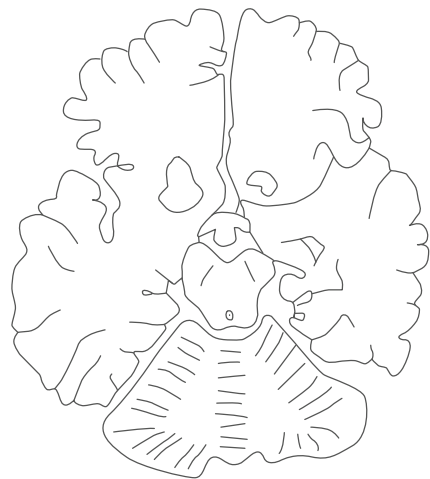
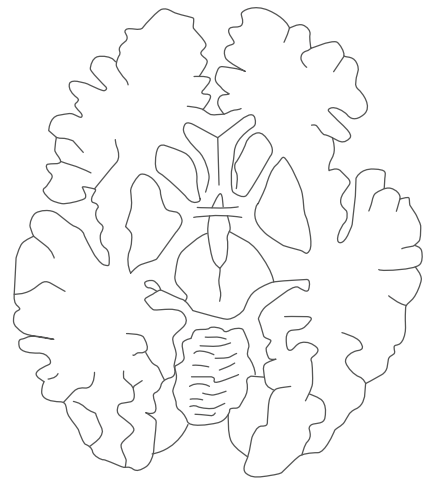

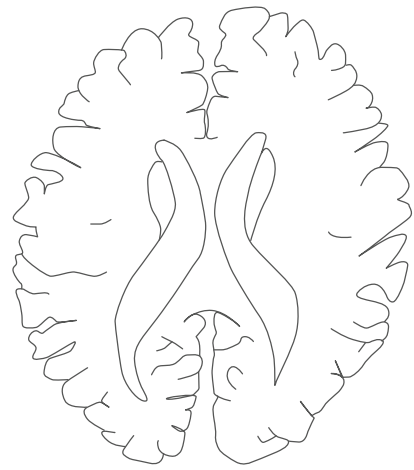
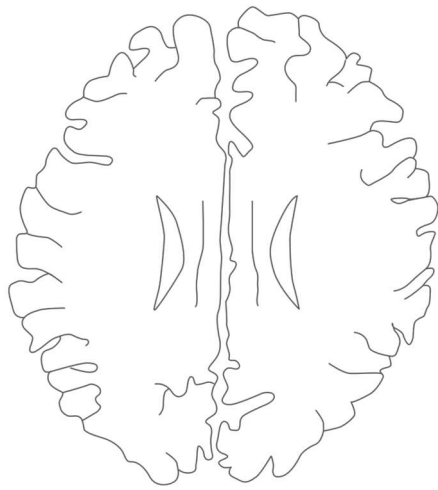
pons

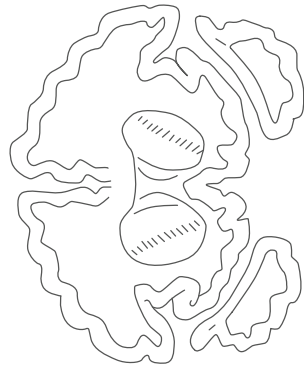
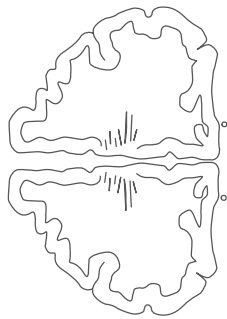
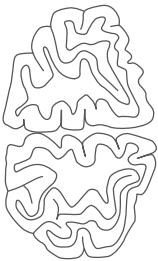
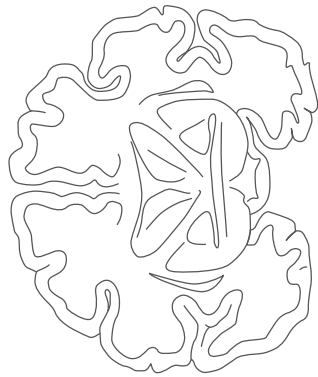
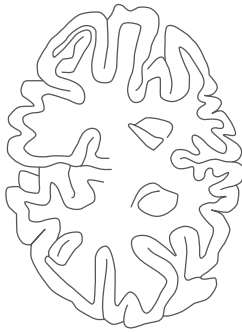
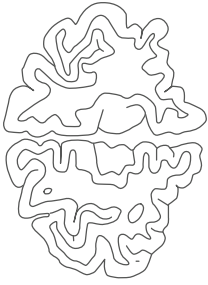
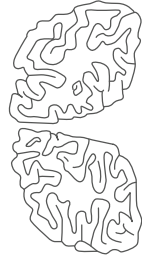
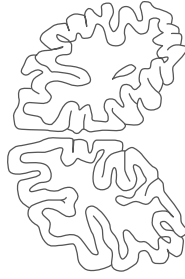
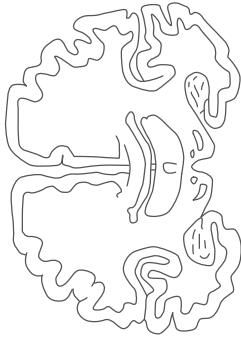
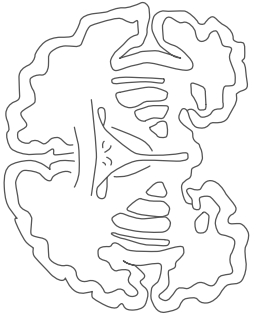
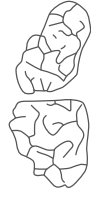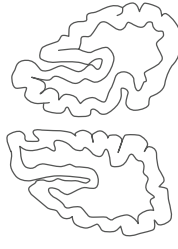
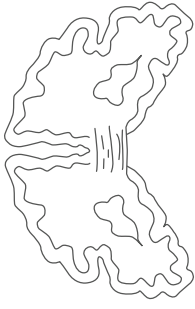
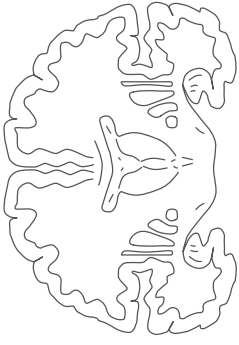


low pons



medulla





R

L

R

L

R

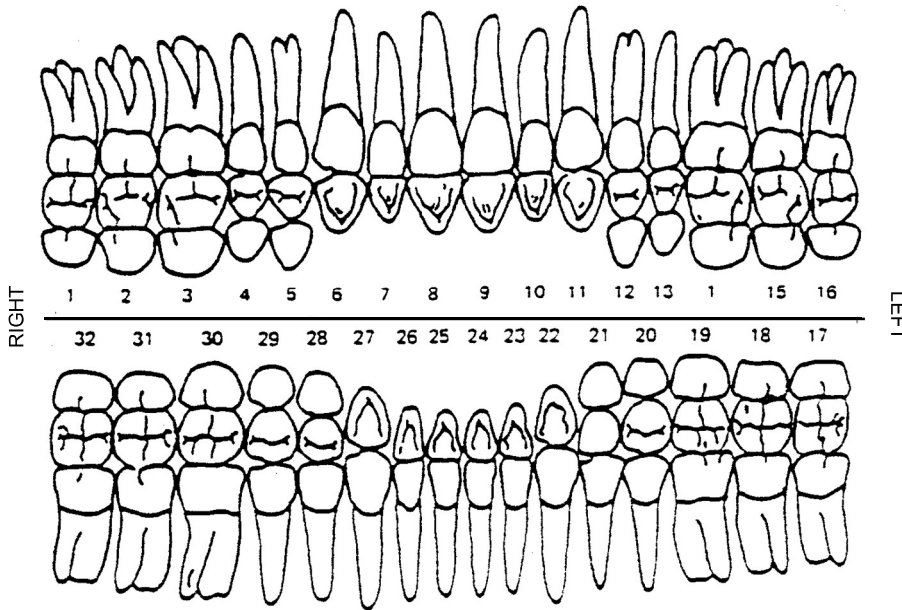
L

R

L

MARK ALL EXISTING RESTORATIONS & MISSING TEETH ON THIS CHART _____

Race _____



Circle descriptive term
Prosthetic appliances present
Maxilla

- Full denture
- Partial denture
- Fixed bridge

Mandible

- Full denture
- Partial denture
- Fixed bridge

Describe completely all prosthetic appliances or fixed bridges _____

Stains on teeth

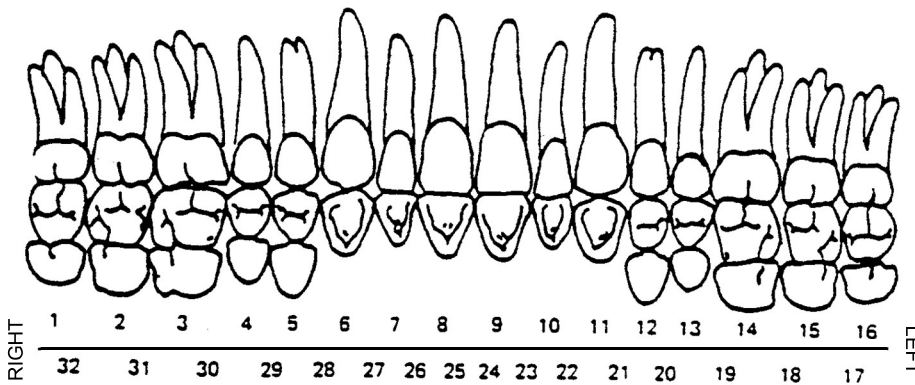
- Slight
- Moderate
- Severe

MARK ALL CARIES ON THIS CHART

Outline all caries & mark out 'X' for all missing teeth Circle descriptive term

Relationship

- Normal
- Undershot
- Overbite



Periodontal Condition

- Excellent
- Average
- Poor

Calculus

- Slight
- Moderate
- Severe